

# BASCOM PALMER EYE INSTITUTE

# XLII

Inter-American Course in Clinical  
Ophthalmology - Virtual Edition

Curso Interamericano de Oftalmología  
Clínica - Edición Virtual

---

November 21, 2020  
21 de noviembre de 2020



**XLII CURSO INTERAMERICANO DE OFTALMOLOGÍA CLÍNICA  
EDICIÓN VIRTUAL**

**Sábado, 21 de noviembre de 2020**

**Directores del Curso / Course Directors**



**Dr. Carol L. Karp**  
Professor of Ophthalmology  
Bascom Palmer Eye Institute  
University of Miami School of  
Medicine

**Dr. Eduardo C. Alfonso**  
Chairman  
Bascom Palmer Eye Institute  
Professor of Ophthalmology  
University of Miami School of Medicine

**Dr. Paul F. Palmberg**  
Professor of Ophthalmology  
Bascom Palmer Eye Institute  
University of Miami School of  
Medicine

**XLII INTER-AMERICAN COURSE IN CLINICAL OPHTHALMOLOGY  
VIRTUAL EDITION**

**Saturday, November 21, 2020**

## INDICE / TABLE OF CONTENTS

Enlace directo al hacer clic sobre el nombre del conferencista  
Click on speaker name to link to page

Patrocinadores / Educational Supporters .....	5
Calendario de Eventos / Upcoming Events .....	6
Programa (español).....	7
Program (English).....	11
Conferencistas / Speakers .....	15
Expositores Comerciales / Exhibitors .....	18
<b>Retina</b>	
Goldhardt, Raquel .....	22
Sridhar, Jayanth. ....	25
Flynn Jr., Harry W. ....	30
Haddock, Luis, J. ....	33
Smiddy, William E. ....	37
<b>Glaucoma</b>	
Swaminathan, Swarup S. ....	39
Palmberg, Paul F. ....	43
Bitrian, Elena .....	45
Battle, Juan .....	49
<b>Cirugía de Cataratas / Refractiva – Cataract / Refractive Surgery</b>	
Yoo, Sonia H. ....	53
Tonk, Rahul S. ....	56
Cabot, Florence .....	60
Culbertson, William W. ....	63
Donaldson, Kendall E. ....	66
<b>Superficie Ocular / Córnea - Ocular Surface / Cornea</b>	
Martinez Martinez, Jaime D. ....	74
Chang, Victoria .....	79
Gibbons, Allister G. ....	84
O'Brien, Terrence P. ....	87
Perez, Victor L. ....	93

**Oftalmología Pediátrica / Pediatric Ophthalmology**

McKeown, Craig A. ....97  
Osigian, Carla J. ....101  
Capo, Hilda .....106

**Oculoplástica / Oculoplastics**

Tse, Brian C. ....110  
Rong, Andrew .....113  
Johnson, Thomas E. ....116  
Lee, Bradford W. ....122  
Alabiad, Chris R. ....126  
Tse, David T. ....130

**Neuro Oftalmología / Neuro Ophthalmology**

Mendoza, Carlos E. ....134  
Lam, Byron L. ....139  
Pasol, Joshua. ....142

**Uveítis**

Galor, Anat .....146  
Perez, Victor L. ....150  
Goldhardt, Raquel. ....153  
Davis, Janet L. ....157  
Albini, Thomas A. ....160

**Oncología / Oncology**

Karp, Carol L. ....164  
Harbour, William J. ....169  
Correa, Zelia M. ....173  
Dubovy, Sander R. ....176

**Telesalud / Oftalmología Global – Telehealth / Global Ophthalmology**

Habash, Ranya G. ....183  
Ansari, Zubair .....187

**Baja Visión / Low Vision**

Sperazza, Laura C.....191

**APOYO EDUCATIVO / EDUCATIONAL SUPPORTERS**

Gracias por el apoyo educacional de:  
Thanks to our educational supporters:

**Bausch & Lomb**

**Novartis Pharmaceuticals**

**Regeneron Pharmaceuticals**

**PATROCINADORES / SPONSORS**

Gracias a nuestros auspiciadores:  
Thanks to our sponsors:

**Alcon**

**Johnson & Johnson**

## CALENDARIO DE EVENTOS / UPCOMING EVENTS

### **Practical Applications of Optical Coherence Tomography Technologies in the Diagnosis and Management of Ocular Disease – VIRTUAL EDITION**

Date: December 5, 2020  
Time: 8:00am – 3:30pm  
Course Directors: Richard K. Lee, MD, PhD and Jorge A. Fortun, MD  
CME Credits: 4.5

### **MIGS-travaganza: Beyond MIGS – VIRTUAL EDITION**

Date: January 28, 2021  
Time: 12:55pm – 4:30pm  
Course Directors: Ta Chen Peter Chang, MD, Sarah R. Wellik, MD, and Luis E. Vazquez, MD, PhD  
CME Credits: 3.0

### **Angiogenesis, Exudation, and Degeneration 2021 – VIRTUAL EDITION**

Date: February 12-13, 2021  
Course Directors: Philip J. Rosenfeld, MD, PhD, Harry W. Flynn, Jr., MD, and Thomas A. Albini, MD  
CME Credits: 9.0

### **Interactive Consultations in Cornea, Cataract and Refractive Surgery 2021 – VIRTUAL EDITION**

Date: February 27, 2021  
Course Directors: Guillermo Amescua, MD, Kendall E. Donaldson, MD, MS, and Mohamed Abou Shousha, MD, PhD  
CME Credits: TBD

### **57<sup>th</sup> Annual Residents' Days**

Date: June 19, 2021  
Location: Jose Berrocal Auditorium, Bascom Palmer Eye Institute  
Course Directors: Harry W. Flynn, Jr. MD and Steven J. Gedde, MD  
CME Credits: TBD

### **Joint XLIII Inter-American Course in Clinical Ophthalmology and XXVII Pan-American Regional Course**

Date: November 21-24, 2021  
Location: Doubletree by Hilton Hotel Miami Airport Miami, FL  
Course Directors: Eduardo C. Alfonso, MD, Carol L. Karp, MD, and Paul F. Palmberg, MD, PhD

## PROGRAMA

### Sábado 21 de noviembre de 2020

*\*Todos los horarios son EST (Hora estándar del Este)*

Programa sujeto a cambios

**8:00 am Apertura de las Exhibiciones Virtuales en Vivo**

**8:45 am Palabras de Bienvenida**

**9:00 am Retina**

Moderadores: Dr. William E. Smiddy y Dr. Luis J. Haddock

La Vida de un Pólipo

**Dr. Raquel Goldhardt**

Maculopatía Multifocal

**Dr. Jorge A. Fortun**

¡No me Olvides!

**Dr. Jayanth Sridhar**

Respuesta de la Retinopatía Proliferativa a Panfotocoagulación y Tratamiento Anti-antigénico Demostrado por Angiografía con OCT

**Dr. Harry W. Flynn, Jr.**

No Estamos Convencidos

**Dr. Luis J. Haddock**

Cuidado: Puede Suceder Cuando Usted Menos lo Espera

**Dr. William E. Smiddy**

Discusión

**9:25 am Glaucoma**

Moderadores: Dr. Paul F. Palmberg y Dr. Elena Bitrián

Segunda Opinión "¿Necesito una PIO aún más Baja?"

**Dr. Swarup S. Swaminathan**

Caso Misterioso de Hipotonía

**Dr. Paul F. Palmberg**

Ojos Pequeños, "Soluciones Grandes"

**Dr. Elena Bitrián**

Lo que he Aprendido Usando el Microshunt Durante 10 años

**Dr. Juan Batlle**

Panel:

"¿Cuál es el Mejor Abordaje Inicial al Glaucoma de Angulo Cerrado agudo?"

Dr. Juan Batlle, Dra. Elena Bitrián, Dr. Paul F. Palmberg, Dr. Luis E. Vázquez y Dr. Swarup Swaminathan

\* PDR – Retinopatía diabética proliferativa. NVD – neovascularización del disco

\*\* PRP – Pan Retinal Photocoagulation

\*\*\* VEGF- factor de crecimiento vascular endotelial

\*\*\*\* OCTA – angiografía por tomografía de coherencia óptica

## PROGRAMA

- 9:50 am**      **Cirugía de Cataratas/Refractiva**  
Moderadores: Dr. Sonia H. Yoo y Dr. Rahul S. Tonk  
Cirugía de Cataratas en la Ausencia de Soporte Zonular  
**Dr. Sonia H. Yoo**  
Queratomileusis para Corneas Anormales  
**Dr. Rahul S. Tonk**  
Manejo de Cataratas Blancas  
**Dr. Florence Cabot**  
Cirugía de Cataratas en una Cámara Anterior Estrecha  
**Dr. William W. Culbertson**  
Impacto del Astigmatismo Irregular en la Cirugía de Cataratas  
**Dr. Kendall E. Donaldson**  
Discusión
- 10:15 am**      **Exhibiciones Virtuales / Receso**
- 10:45 am**      **Superficie Ocular /Córnea**  
Moderadores: Dr. Guillermo Amescua y Dr. Alfonso L. Sabater  
Adelgazamiento Atípico: Ayuda Por Favor!  
**Dr. Jaime D. Martínez Martínez**  
Edema Post Facó: ¿Ahora qué Hago?  
**Dr. Victoria Chang**  
Cuando la Ceguera “Corneal” continúa  
**Dr. Allister G. Gibbons**  
Rotación de Doctores en Conjuntivitis Crónica  
**Dr. Terrence P. O'Brien**  
Queratinización Severa de la Superficie Ocular en Pacientes  
Pediátricos: Una Idea para Digerir  
**Dr. Victor L. Pérez**  
Discusión
- 11:25 am**      **Oftalmología Pediátrica**  
Moderadores: Dr. Hilda Capó y Dr. Craig A. McKeown  
Caso 1  
**Dr. Kara M. Cavuoto**  
Caso 2  
**Dr. Craig A. McKeown**  
Caso 3  
**Dr. Carla J. Osigian**  
Caso 4  
**Dra. Hilda Capó**  
Discusión

## PROGRAMA

- 11:50 am**      **Oculoplástica**  
Moderador: Dr. Thomas E. Johnson  
Carcinoma Basocelular Periocular Grande Tratado con Vismodegib  
**Dr. Brian C. Tse**  
Visitando el Pasado  
**Dr. Andrew Rong**  
El Otro Tumor Maligno de la Glándula Lacrimal  
**Dr. Thomas E. Johnson**  
Los Riesgos Asociados con la Inyección Periocular de Ácido Deoxicólico para el Prolapso de la Grasa Orbital  
**Dr. Bradford W. Lee**  
Piensa Dos Veces – Manejo de una Lesión Desafiante del Nervio Óptico  
**Dr. Chris R. Alabiad**  
Mapeo Automatizado, sin Contacto, de Topografía Facial, Impresión Tridimensional y Fundición de Silicona de Prótesis Orbitaria  
**Dr. David T. Tse**  
Discusión
- 12:20 pm**      **Neuro Oftalmología**  
Moderador: Dr. Carlos E. Mendoza  
Patrones de OCT (Tomografía de Coherencia Óptica) de la Perdida del Complejo Ganglionar Celular en Neuro-oftalmología  
**Dr. Carlos E. Mendoza**  
No Pierdas los Nervios  
**Dr. Byron L. Lam**  
Lección Aprendida de un Joven de 21 años con Neuropatía Óptica  
**Dr. Joshua Pasol**  
Discusión
- 12:40 pm**      **Exhibiciones Virtuales / Receso**
- 1:10 pm**      **Uveítis**  
Moderador: Dr. Raquel Goldhardt  
  
Riñón y Ojo  
**Dr. Anat Galor**  
Uveítis Herpética  
**Dr. Victor L. Perez**  
Hipopión Sangriento  
**Dr. Raquel Goldhardt**  
Edema Macular Cistoide Recalcitrante  
**Dr. Janet L. Davis**  
Más Riñones  
**Dr. Thomas A. Albini**  
Discusión

## PROGRAMA

- 1:40 pm**      **Oncología**  
Moderador: Dr. Carol L. Karp  
La Masa Misteriosa  
**Dr. Carol L. Karp**  
Ascendencia Genética en Oncología Ocular  
**Dr. J. William Harbour**  
Manejo Complejo del Melanoma Coroideo  
**Dr. Zelia M. Correa**  
El Asunto es el Tejido  
**Dr. Sander R. Dubovy**  
Discusión
- 2:00 pm**      **Telesalud/ Oftalmología Global**  
Moderadores: Dra. Ranya G. Habash y Dr. Zubair Ansari  
Innovaciones Tecnológicas en el *Bascom Palmer Eye Institute*  
**Dr. Ranya G. Habash**  
Modelos Emergentes y la Colaboración en la Oftalmología Global  
**Dr. Zubair Ansari**  
Discusión
- 2:10 pm**      **Baja Visión**  
Rehabilitación para los Pacientes de Visión Disminuida  
**Dr. Laura C. Sperazza**
- 2:30 pm**      **Rifa y Palabras de Cierre**
- 2:40 pm**      **Suspensión de las Ponencias /Exhibiciones Virtuales en Vivo**  
**Abiertas/Conozca a los Conferencistas**
- 3:40 pm**      **Suspensión de las Exhibiciones Virtuales en Vivo \***

*\*Las exhibiciones virtuales seguirán estando disponibles para la revisión de los participantes hasta el viernes, el 27 de noviembre, pero posiblemente no atendidas por personal.*

## PROGRAM AGENDA

**Saturday November 21, 2020**

*\*All Times are EST*

Agenda is subject to change

- 8:00 am**      **Live Virtual Exhibits Open**
- 8:45 am**      **Opening Remarks**
- 9:00 am**      **Retina**  
Moderators: William E. Smiddy, MD and Luis J. Haddock, MD
- The Life of a Polyp  
**Raquel Goldhardt, MD**  
Multifocal Maculopathy  
**Jorge A. Fortun, MD**  
Don't Forget About Me  
**Jayanth Sridhar, MD**  
Response of PDR/NVD to PRP and Anti-VEGF as Shown by OCTA  
**Harry W. Flynn, Jr., MD**  
ARN'T Convinced  
**Luis J. Haddock, MD**  
Beware: It Can Happen When You Least Expect It  
**William E. Smiddy, MD**  
Discussion
- 9:25 am**      **Glaucoma**  
Moderators: Paul F. Palmberg, MD, PhD and Elena Bitrian, MD
- Second Opinion "Do I Need an Even Lower IOP?"  
**Swarup S. Swaminathan, MD**  
Mysterious Case of Hypotony  
**Paul F. Palmberg, MD, PhD**  
Little Eyes, "Big Solutions"  
**Elena Bitrian, MD**  
What I Have Learned Using the Microshunt for 10 Years  
**Juan Batlle, MD**  
Panel: "What is the Best Initial Approach to Acute Angle Closure?"  
Juan Batlle, MD, Elena Bitrian, MD, Paul F. Palmberg, MD, PhD, Luis E. Vazquez, MD, PhD, and Swarup S. Swaminathan, MD
- 9:50 am**      **Cataract/Refractive Surgery**  
Moderators: Sonia H. Yoo, MD and Rahul S. Tonk, MD
- Cataract Surgery in the Absence of Zonular Support  
**Sonia H. Yoo, MD**  
Keratomileusis for Abnormal Corneas  
**Rahul S. Tonk, MD**  
Management of White Cataracts  
**Florence Cabot, MD**

## PROGRAM AGENDA

Cataract Surgery in a Narrow Anterior Chamber

**William W. Culbertson, MD**

Impact of Irregular Astigmatism on Cataract Surgery

**Kendall E. Donaldson, MD, MS**

Discussion

**10:15 am Virtual Exhibits/Break**

**10:45 am Ocular Surface/Cornea**

Moderators: Guillermo Amescua, MD and Alfonso L. Sabater, MD, PhD

Atypical Thinning: Help Please!

**Jaime D. Martinez Martinez, MD**

Edema Post Phaco: Now What?

**Victoria Chang, MD**

When "Corneal" Blindness Continues

**Allister G. Gibbons, MD**

Chronic Conjunctivitis and Revolving Eye Doctors

**Terrence P. O'Brien, MD**

Severe Ocular Surface Keratinization in Pediatric Patients: A Thought to Digest

**Victor L. Perez, MD**

Discussion

**11:25 am Pediatric Ophthalmology**

Moderators: Hilda Capo, MD and Craig A. McKeown, MD

Case 1

**Kara M. Cavuoto, MD**

Case 2

**Craig A. McKeown, MD**

Case 3

**Carla J. Osigian, MD**

Case 4

**Hilda Capo, MD**

Discussion

**11:50 am Oculoplastics**

Moderator: Thomas E. Johnson, MD

Large Periocular Basal Cell Carcinoma Treated with Vismodegib

**Brian C. Tse, MD**

Revisiting the Past

**Andrew Rong, MD**

The Other Lacrimal Gland Malignant Tumor

**Thomas E. Johnson, MD**

Risks Associated with Periocular Injection of Deoxycholic Acid for Orbital Fat Prolapse

**Bradford W. Lee, MD, MSC**

Think Twice – Managing a Challenging Optic Nerve Lesion

**Chris R. Alabiad MD**

## PROGRAM AGENDA

Automated Noncontact Facial Topography Mapping, 3-Dimensional Printing,  
and Silicone Casting of Orbital Prosthesis

**David T. Tse, MD**

Discussion

**12:20 pm**

### **Neuro Ophthalmology**

Moderator: Carlos E. Mendoza, MD

OCT Patterns of Ganglion Cell Complex Loss in Neuro-Ophthalmology

**Carlos E. Mendoza, MD**

Don't Lose your Nerve

**Byron L. Lam, MD**

Lesson Learned from a 21-Year-Old with an Optic Neuropathy

**Joshua Pasol, MD**

Discussion

**12:40 pm**

### **Virtual Exhibits/Break**

**1:10 pm**

### **Uveitis**

Moderator: Raquel Goldhardt, MD, FACS

Kidney and Eye

**Anat Galor, MD, MSPH**

Herpetic Uveitis

**Victor L. Perez, MD**

Bloody Hypopyon

**Raquel Goldhardt, MD, FACS**

Recalcitrant Cystoid Macular Edema

**Janet L. Davis, MD**

More Kidney

**Thomas A. Albini, MD**

Discussion

**1:40 pm**

### **Oncology**

Moderator: Carol L. Karp, MD

Mystery Mass

**Carol L. Karp, MD**

Genetic Ancestry in Ocular Oncology

**J. William Harbour, MD**

Complex Management of Choroidal Melanoma

**Zelia M. Correa, MD, PhD**

Tissue is the Issue

**Sander R. Dubovy, MD**

Discussion

## PROGRAM AGENDA

- 2:00 pm**      **Telehealth/Global Ophthalmology**  
Moderators: Ranya G. Habash, MD and Zubair Ansari, MD  
Technological Innovations at Bascom Palmer Eye Institute  
**Ranya G. Habash, MD**  
Emerging Models and Collaboration in Global Ophthalmology  
**Zubair Ansari, MD**
- 2:10 pm**      **Low Vision**  
Vision Rehabilitation for Low Vision Patients  
**Laura C. Sperazza, MD**
- 2:30 pm**      **Raffle and Closing Remarks**
- 2:40 pm**      **Lectures Adjourn/Live Virtual Exhibits Open /Meet the Faculty**
- 3:40 pm**      **Live Virtual Exhibits Adjourn\***

*\*virtual exhibits will continue to be available for all registrants to view, until Friday, November 27, but may not be staffed.*

**CONFERENCISTAS Y MODERADORES**  
**SPEAKERS AND MODERATORS**

**Dr. Chris R. Alabiad**

Associate Professor of Clinical  
Ophthalmology  
Bascom Palmer Eye Institute  
Miami, FL, USA

**Dr. Thomas A. Albini**

Professor of Clinical Ophthalmology  
Bascom Palmer Eye Institute  
Miami, FL, USA

**Dr. Guillermo Amescua**

Associate Professor of Clinical  
Ophthalmology  
Bascom Palmer Eye Institute  
Miami, FL, USA

**Dr. Zubair Ansari**

Associate Professor of Clinical  
Ophthalmology  
Bascom Palmer Eye Institute  
Miami, FL, USA

**Dr. Juan F. Batlle**

Chief of Ophthalmology, Elias Santana  
Hospital  
President, Laser Center  
Santo Domingo, Dominican Republic

**Dr. Elena Bitrian**

Associate Professor of Clinical  
Ophthalmology  
Bascom Palmer Eye Institute  
Miami, FL, USA

**Dr. Florence Cabot**

Assistant Professor of Clinical  
Ophthalmology  
Bascom Palmer Eye Institute  
Miami, FL, USA

**Dr. Hilda Capo**

Professor of Clinical Ophthalmology  
John T. Flynn Chair in Ophthalmology  
Bascom Palmer Eye Institute  
Miami, FL, USA

**Dr. Kara M. Cavuoto**

Associate Professor of Clinical  
Ophthalmology  
Bascom Palmer Eye Institute  
Miami, FL, USA

**Dr. Victoria Chang**

Assistant Professor of Clinical  
Ophthalmology  
Bascom Palmer Eye Institute  
Naples, FL, USA

**Dr. Zelia M. Correa**

Professor of Ophthalmology  
Bascom Palmer Eye Institute  
Miami, FL, USA

**Dr. William W. Culbertson**

Professor of Ophthalmology  
Lou Higgins Chair in Ophthalmology  
Bascom Palmer Eye Institute  
Miami, FL, USA

**Dr. Janet L. Davis**

Professor of Ophthalmology  
Leach Chair in Ophthalmology,  
Bascom Palmer Eye Institute  
Miami, FL, USA

**Dr. Kendall E. Donaldson**

Professor of Clinical Ophthalmology  
Bascom Palmer Eye Institute at  
Plantation, Plantation, FL, USA

**Dr. Sander R. Dubovy**

Professor of Ophthalmology  
Victor T. Curtin Chair in Ophthalmology  
Bascom Palmer Eye Institute  
Miami, FL, USA

**Dr. Harry W. Flynn, Jr.**

Professor of Ophthalmology  
Bascom Palmer Eye Institute  
Miami, FL, USA

**CONFERENCISTAS Y MODERADORES**  
**SPEAKERS AND MODERATORS**

**Dr. Jorge A. Fortun**

Associate Professor of Clinical  
Ophthalmology  
Medical Director, Bascom Palmer Eye  
Institute at Palm Beach Gardens  
Palm Beach Gardens, FL, USA

**Dr. Anat Galor**

Associate Professor of Ophthalmology  
Bascom Palmer Eye Institute  
Miami, FL, USA

**Dr. Allister G. Gibbons**

Assistant Professor of Clinical  
Ophthalmology  
Bascom Palmer Eye Institute  
Naples, FL, USA

**Dr. Raquel Goldhardt**

Associate Professor of Clinical  
Ophthalmology  
Bascom Palmer Eye Institute  
Miami, FL, USA

**Dr. Ranya G. Habash**

Assistant Professor of Clinical  
Ophthalmology  
Bascom Palmer Eye Institute  
Miami, FL, USA

**Dr. Luis J. Haddock**

Assistant Professor of Clinical  
Ophthalmology  
Bascom Palmer Eye Institute  
Palm Beach, FL, USA

**Dr. J. William Harbour**

Professor of Ophthalmology  
Mark J. Daily Chair in Ophthalmology  
Bascom Palmer Eye Institute  
Miami, FL, USA

**Dr. Thomas E. Johnson**

Professor of Clinical Ophthalmology  
Bascom Palmer Eye Institute  
Miami, FL, USA

**Dr. Byron L. Lam**

Professor of Ophthalmology  
Bascom Palmer Eye Institute  
Miami, FL, USA

**Dr. Bradford W. Lee**

Assistant Professor of Clinical  
Ophthalmology  
Bascom Palmer Eye Institute  
Palm Beach, FL, USA

**Dr. Jaime D. Martinez Martinez**

Assistant Professor of Clinical  
Ophthalmology  
Bascom Palmer Eye Institute  
Miami, FL, USA

**Dr. Craig A. McKeown**

Professor of Clinical Ophthalmology  
Bascom Palmer Eye Institute  
Miami, FL, USA

**Dr. Carlos E. Mendoza**

Assistant Professor of Clinical  
Ophthalmology  
Bascom Palmer Eye Institute  
Miami, FL, USA

**Dr. Terrence P. O'Brien**

Professor of Ophthalmology  
Charlotte Breyer Rodgers Chair in  
Ophthalmology  
Bascom Palmer Eye Institute  
Palm Beach Gardens, FL, USA

**Dr. Carla J. Osigian**

Assistant Professor of Clinical  
Ophthalmology  
Bascom Palmer Eye Institute  
Naples, FL, USA

**Dr. Joshua Pasol**

Associate Professor of Clinical  
Ophthalmology  
Bascom Palmer Eye Institute  
Miami, FL, USA

**CONFERENCISTAS Y MODERADORES**  
**SPEAKERS AND MODERATORS**

**Dr. Victor L. Pérez**

Professor of Ophthalmology  
Stephen and Frances Foster  
Distinguished Professor of  
Ocular Immunology and Inflammation  
Duke University School of Medicine  
Durham, NC, USA

**Dr. Andrew Rong**

Assistant Professor of Clinical  
Ophthalmology  
Bascom Palmer Eye Institute  
Miami, FL, USA

**Dr. Alfonso L. Sabater**

Assistant Professor of Clinical  
Ophthalmology  
Bascom Palmer Eye Institute  
Miami, FL, USA

**Dr. William E. Smiddy**

Professor of Ophthalmology  
M. Brenn Green Chair in Ophthalmology  
Bascom Palmer Eye Institute  
Naples, FL, USA

**Dr. Laura C. Sperazza**

Director of Vision Rehabilitation  
Services  
Lighthouse Guild  
New York, NY, USA

**Dr. Jayanth Sridhar**

Assistant Professor of Clinical  
Ophthalmology  
Bascom Palmer Eye Institute  
Miami, FL, USA

**Dr. Swarup S. Swaminathan**

Assistant Professor of Clinical  
Ophthalmology  
Bascom Palmer Eye Institute  
Miami, FL, USA

**Dr. Rahul S. Tonk**

Assistant Professor of Clinical  
Ophthalmology  
Bascom Palmer Eye Institute  
Miami, FL, USA

**Dr. Brian C. Tse**

Assistant Professor of Clinical  
Ophthalmology  
Bascom Palmer Eye Institute  
Miami, FL, USA

**Dr. David T. Tse, MD**

Professor of Ophthalmology  
Dr. Nasser Ibrahim Al-Rashid Chair in  
Ophthalmology  
Bascom Palmer Eye Institute  
Miami, FL, USA

**Dr. Luis E. Vazquez**

Assistant Professor of Clinical  
Ophthalmology  
Bascom Palmer Eye Institute  
Miami, FL, USA

**Dr. Sonia H. Yoo**

Professor of Ophthalmology  
Greentree Pruett Hickman Chair in  
Ophthalmology  
Bascom Palmer Eye Institute  
Miami, FL, USA

## EXPOSITORES COMERCIALES/EXHIBITORS

### **Appasamy Associates**

Sridhar Galli  
westasia@appasamy.com

### **Aurolab**

Uma Mahi  
aurolab@aurolab.com

### **Bascom Palmer Eye Institute (BPEI)**

Continuing Medical Education  
curso@med.miami.edu

### **Creative Latin Media**

Laura Malkin Stuart  
lmalkinstuart@clatinmedia.com

### **Device Optical**

Ricardo Mazur  
info@deviceoptical.com

### **Epsilon**

Mohammed Ibrahim  
Epsilonusa1@gmail.com

### **Franja Corporation**

Karol Rivera  
gerentecom@franjapublicaciones.com

### **Good-Lite Co.**

Arturo Sanchez  
jasl@good-lite.com

### **Jaypee -Highlights of Ophthalmology**

Sheyla Marengo  
sheyla@jphmedical.com

### **Mayoristas de Opticas**

Doralice Dolabany  
doralice@mayoristasdeopticas.com

### **Medilex**

Rogelio Dossantos  
office@medilexonline.com

### **Mercoframes Optical Corp.**

Alejandro Gutman  
info@mercoframes.net

### **Nidek**

Hiroko Kotake  
Hiroko\_kotake@nidek.co.jp

### **Ophthalmological Society of the West Indies (OSWI)**

Shannon Hoofatt  
infoatoswi@gmail.com

### **Pan-American Association of Ophthalmology (PAAO)**

Mapy Padilla  
Mapy.padilla@paa.org

### **Rocol**

Paola Gonzalez  
pgonzalez@rocol.com

### **Roland Consult**

Oskar Stasche  
o.stasche@roland-consult.de

### **Stallion Medical, Inc.**

Marcela Gonzalez  
sales@stallionmed.com

### **Star Optical**

Cobi Piwko  
staropti@bellsouth.net

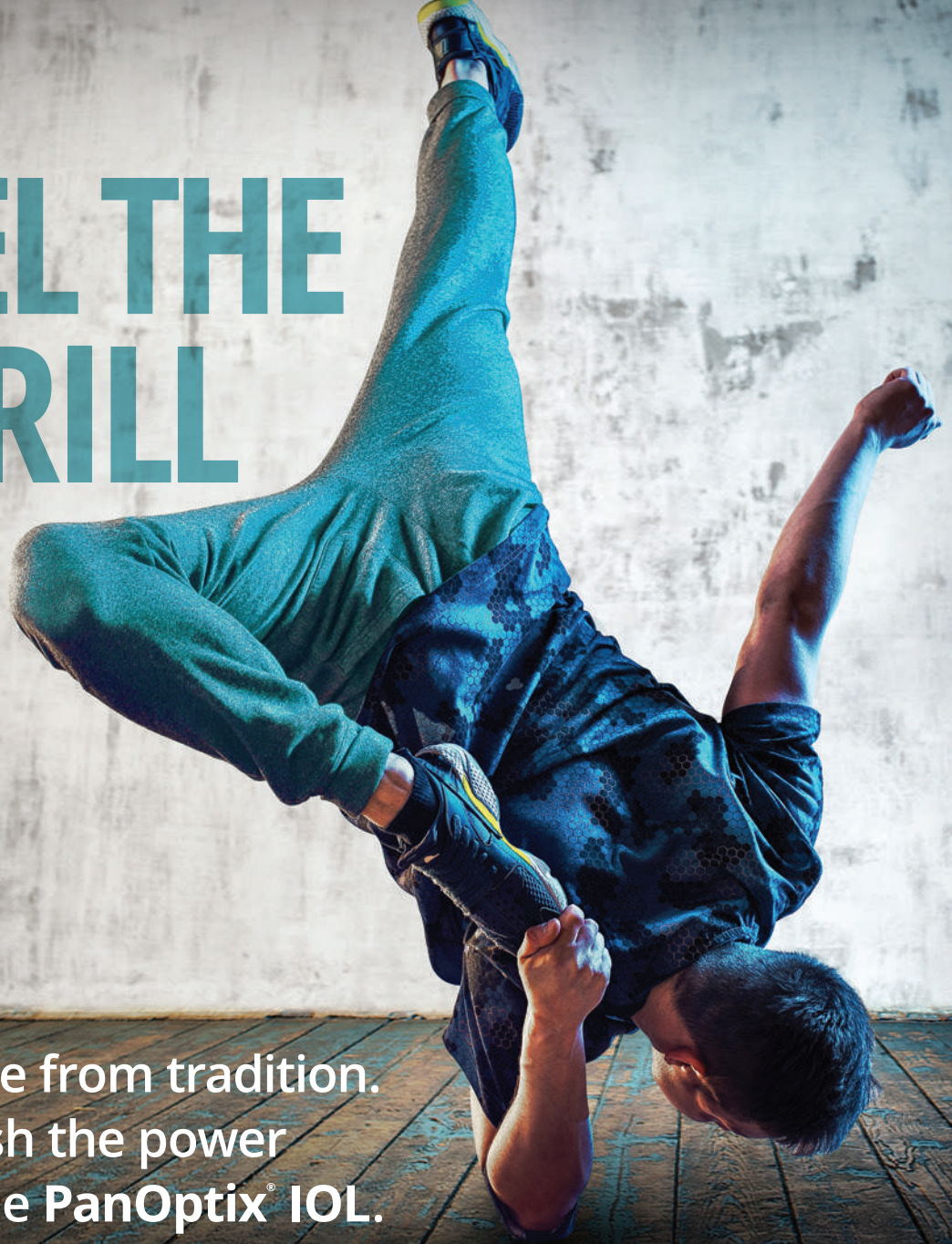### **UHealth International**

Luciano Garrido  
lgarrido@med.miami.edu

### **V-xperience**

Diana Rojas  
diana@v-xperience.com

# FEEL THE THRILL



Break free from tradition.  
Unleash the power  
of the PanOptix® IOL.

#### AcrySof® IQ PanOptix® Family of Trifocal IOLs Important Product Information

**CAUTION:** Federal (USA) law restricts this device to the sale by or on the order of a physician. **INDICATIONS:** The AcrySof® IQ PanOptix® Trifocal IOLs include AcrySof® IQ PanOptix® and AcrySof® IQ PanOptix® Toric IOLs and are indicated for primary implantation in the capsular bag in the posterior chamber of the eye for the visual correction of aphakia in adult patients, with less than 1 diopter of pre-existing corneal astigmatism, in whom a cataractous lens has been removed. The lens mitigates the effects of presbyopia by providing improved intermediate and near visual acuity, while maintaining comparable distance visual acuity with a reduced need for eyeglasses, compared to a monofocal IOL. In addition, the AcrySof® IQ PanOptix® Toric Trifocal IOL is indicated for the reduction of residual refractive astigmatism. **WARNINGS/PRECAUTIONS:** Careful preoperative evaluation and sound clinical judgment should be used by the surgeon to decide the risk/benefit ratio before implanting a lens in a patient with any of the conditions described in the Directions for Use Labeling. Physicians should target emmetropia and ensure that IOL centration is achieved. For the AcrySof® IQ PanOptix® Toric Trifocal IOL, the lens should not be implanted if the posterior capsule is ruptured, if the zonules are damaged or if a primary posterior capsulotomy is planned. Rotation can reduce astigmatic correction. If necessary, lens repositioning should occur as early as possible prior to lens encapsulation. Some visual effects may be expected due to the superposition of focused and unfocused multiple images. These may include some perceptions of halos or starbursts, as well as other visual symptoms. As with other multifocal IOLs, there is a possibility that visual symptoms may be significant enough that the patient will request explant of the multifocal IOL. A reduction in contrast sensitivity as compared to a monofocal IOL may be experienced by some patients and may be more prevalent in low lighting conditions. Therefore, patients implanted with multifocal IOLs should exercise caution when driving at night or in poor visibility conditions. Patients should be advised that unexpected outcomes could lead to continued spectacle dependence or the need for secondary surgical intervention (e.g., intraocular lens replacement or repositioning). As with other multifocal IOLs, patients may need glasses when reading small print or looking at small objects. Posterior capsule opacification (PCO) may significantly affect the vision of patients with multifocal IOLs sooner in its progression than patients with monofocal IOLs. Prior to surgery, physicians should provide prospective patients with a copy of the Patient Information Brochure, available from Alcon, informing them of possible risks and benefits associated with the AcrySof® IQ PanOptix® Trifocal IOLs. **ATTENTION:** Reference the Directions for Use labeling for each IOL for a complete listing of indications, warnings and precautions.

**Alcon**



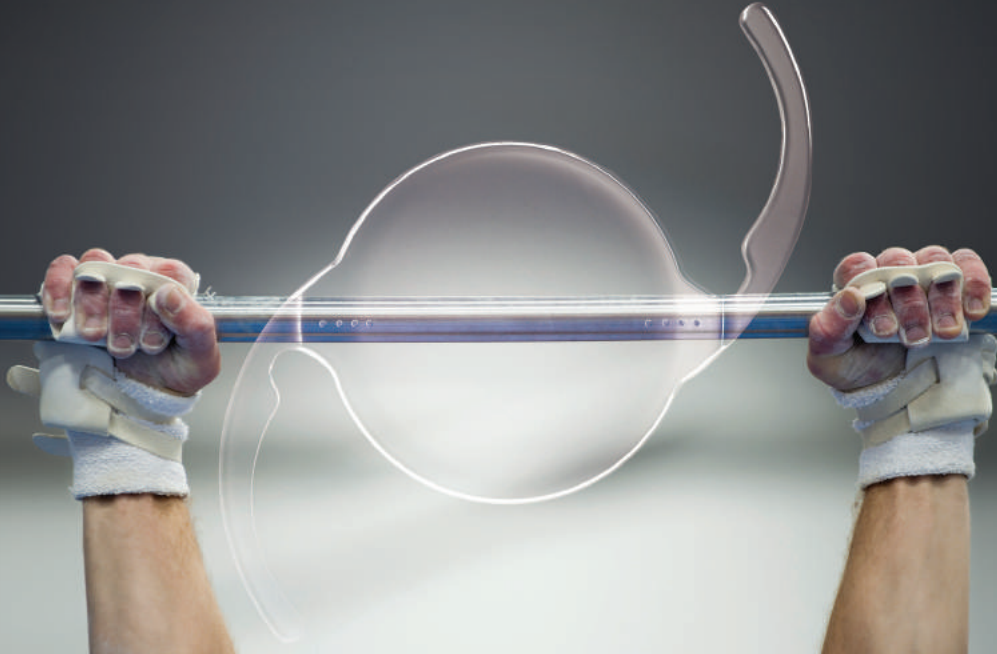
**AcrySof® IQ PanOptix®**  
TRIFOCAL IOL  
TRIFOCAL TORIC IOL

ENLIGHTEN® OPTICAL TECHNOLOGY

# TECNIS® Toric II

## Get a grip on visual performance

NEW squared and frosted haptic design increases the amount of friction between the lens haptic surface and the capsular bag.



To learn more, please visit [www.TecnisToricII.com](http://www.TecnisToricII.com)

#### ABOUT TECNIS® TORIC II IOL

Physicians considering use of the TECNIS® Toric II IOLs should refer to the Directions for Use labeling for a complete list of indications and safety information.

The TECNIS® Toric II 1-Piece posterior chamber lens is indicated for the visual correction of aphakia and pre-existing corneal astigmatism of one diopter or greater in adult patients with or without presbyopia in whom a cataractous lens has been removed by phacoemulsification and who desire improved uncorrected distance vision, reduction in residual refractive cylinder, and increased spectacle independence for distance vision. The device is intended to be placed in the capsular bag.

**IMPORTANT SAFETY INFORMATION:** The most frequently reported cumulative adverse event that occurred during the TECNIS® Toric 1-Piece IOL clinical trial was surgical re-intervention which occurred at a rate of 3.4% (lens repositioning procedures and retinal repair procedures). Rotation of these IOLs away from its intended axis can reduce its astigmatic correction. Misalignment greater than 30° may increase postoperative refractive cylinder. Variability in any of the preoperative measurements can influence patient outcomes. Physicians should weigh the potential risk/benefit ratio for circumstances described in the Directions for Use that could increase complications or impact patient outcomes. Federal law restricts this device to sale, distribution and use by or on the order of a physician.

© Johnson & Johnson Surgical Vision, Inc. 2020 | PP20200TH4683

NOW APPROVED

**TECNIS®**  
Toric II 1-Piece IOL

Toric II

Johnson & Johnson VISION

# **PRESENTACIONES / PRESENTATIONS**

**Retina**

**Glaucoma**

**Cirugía de Cataratas/Refractiva**  
Cataract/Refractive Surgery

**Superficie Ocular /Córnea**  
Ocular Surface/Cornea

**Oftalmología Pediátrica**  
Pediatric Ophthalmology

**Oculoplástica**  
Oculoplastics

**Neuro Oftalmología**  
Neuro Ophthalmology

**Uveitis**

**Oncología**  
Oncology

**Telesalud/ Oftalmología Global**  
Telehealth/Global Ophthalmology

**Baja Visión**  
Low Vision

# Retina

## La Vida de un Pólipo The Life of a Polyp



**Dr. Raquel Goldhardt**

# The Life of a Polyp

*THE LIFE OF A POLYP*

**Raquel Goldhardt M.D. F.A.C.S.**  
 Associate Professor Of Clinical Ophthalmology  
 Bascom Palmer Eye Institute  
 University of Miami Miller School of Medicine  
 Miami VA Medical Center

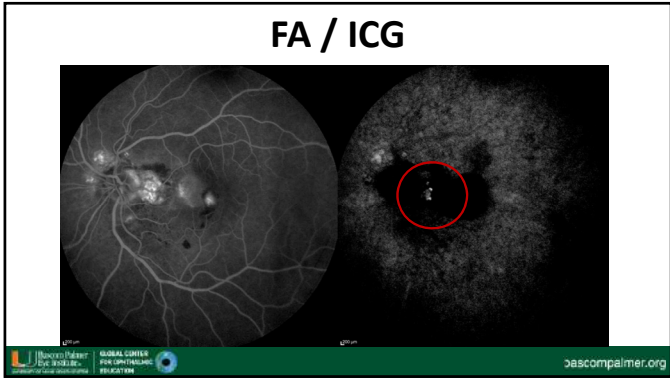
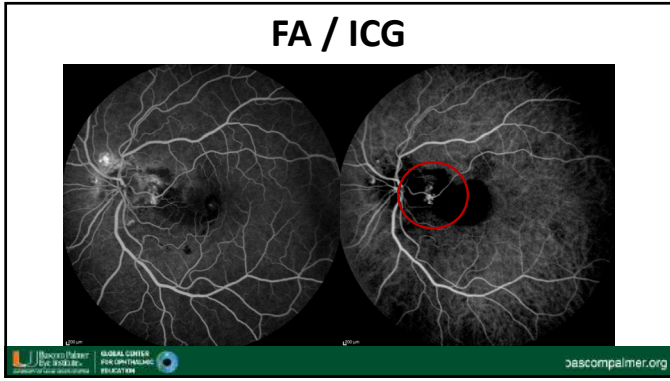
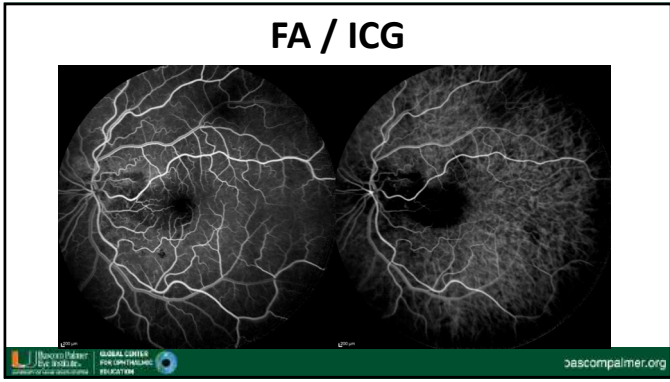
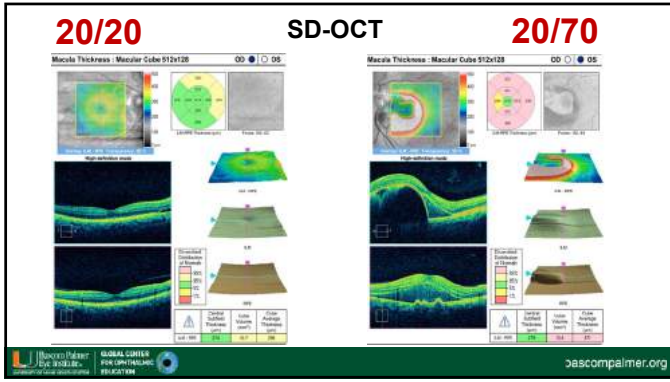
*I have no financial disclosures*

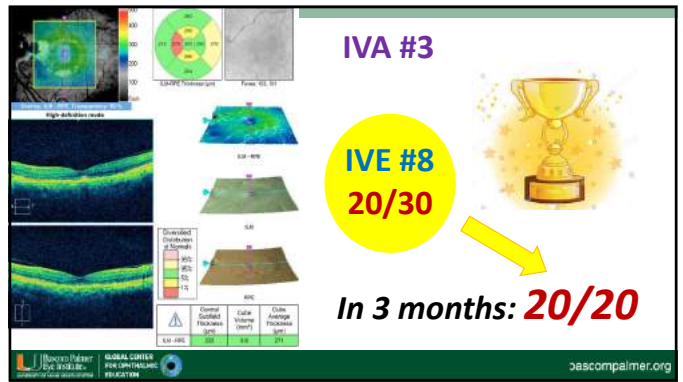
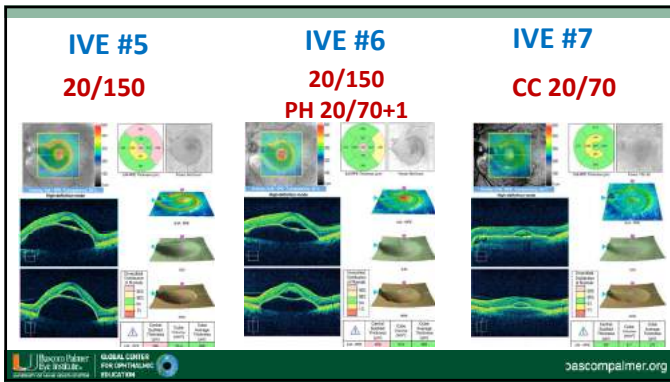
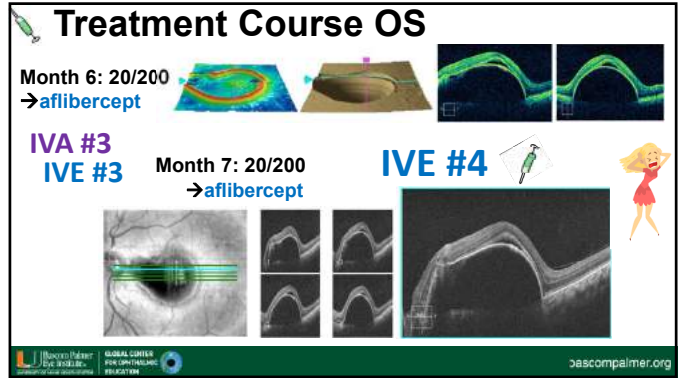
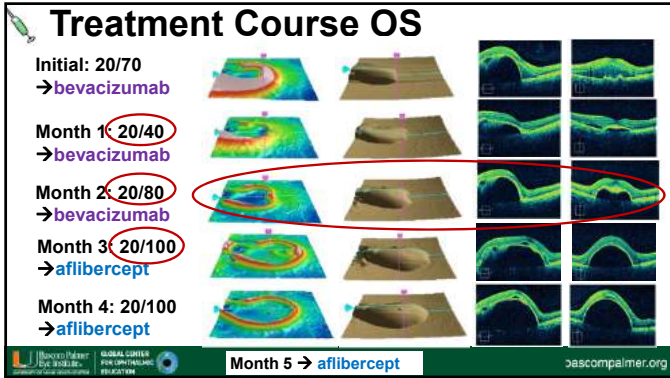
bascompalmer.org

## 70 year-old male

**20/20**      **20/70**

bascompalmer.org






### Polypoidal Choroidal Vasculopathy

#### TAKE HOME POINTS

- ✓ PCV: unilateral disease more often than does AMD
- ✓ More common in Asians, African-Americans and men
- \* Drusen can be present
- RED flag:** patient fail to respond to anti-VEGF, massive submacular hemorrhage and/or orange nodules on clinical examination
- FOR DIAGNOSIS CHOOSE ICG**
- ✓ The combination of half-dose PDT and an anti-VEGF provides added benefit like longer duration of effect and better regression of the aneurysmal lesions \*If your pt travel long distance, consider PDT
- ✓ If they respond to anti-VEGF, the potential but rare complications of PDT can be avoided

GLOBAL CENTER FOR OPTIC NERVE REGENERATION  
sascompalmer.org



# Retina

**¡No me Olvides!**  
Don't Forget About Me



**Dr. Jayanth Sridhar**

## Don't Forget About Me...

CURSO Meeting 2020  
 Jayanth Sridhar MD  
 Associate Professor of Clinical Ophthalmology  
 Bascom Palmer Eye Institute

## Disclosures

No relevant financial  
 Thank you to Dr. Benjamin Lin (PGY-2) for his help with this presentation

## Clinical Presentation

56 yo Latino man presented to BPEI ED with a "purple spot" in his view in his right eye x 4 days during peak of COVID-19 pandemic (April 2020)

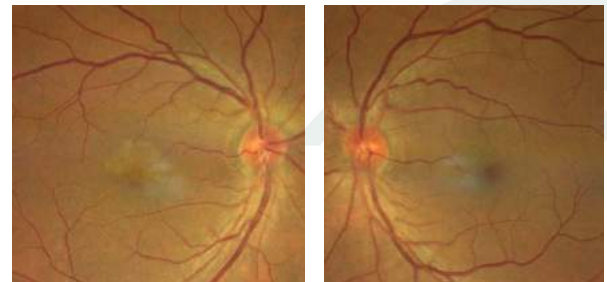## Clinical Presentation

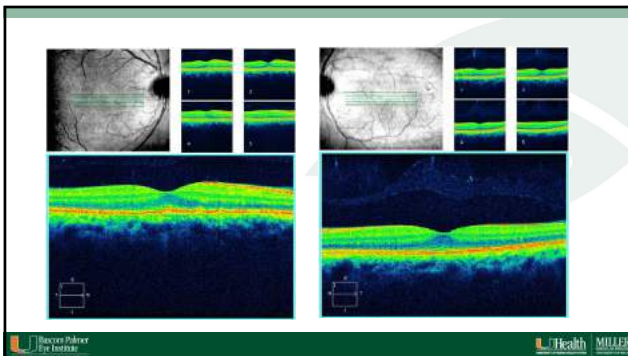
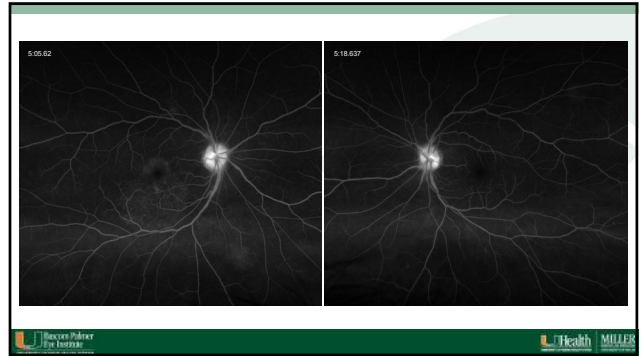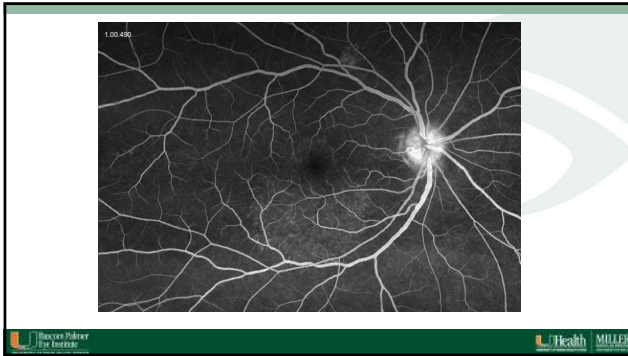
- Past Ocular History: None
- Past Medical History: Gout
- Meds: Allopurinol, Colchicine
- FamHx: No vision loss. No macular degeneration/dystrophy
- Social Hx: Cigarette Smoking (50 pack year), Social EtOH, divorced, no sexual activity per him
- Review of Systems: Negative
- Denies prior trauma, surgery, uveitis

## Exam

	OD	OS
BCVA	20/70 +1	20/25 -1
IOP	11	12
Pupils	PERRL, no APD	PERRL, no APD
Lids/Lashes	Normal	Normal
Conjunctiva/Sclera	White and quiet	White and quiet
Cornea	Clear	Clear
Iris	Round and flat	Round and flat
Anterior Chamber	Deep and quiet	Deep and quiet
Lens	1+ NS	1+ NS
Anterior vitreous	No cell	No cell

	OD	OS
Confrontational VF	Central scotoma	Full
EOMs	Full, ortho	Full, ortho





- ### Differential
- Infectious
    - Syphilis
    - Viral retinitis
    - Tuberculosis retinitis
  - Inflammatory
    - Sarcoid
    - Acute posterior multifocal placoid pigment epitheliopathy (APMPPE)
    - Serpiginous
    - Acute macular neuroretinopathy (AMN)
    - Vogt-Koyanagi-Harada (VKH)
  - Malignant
    - Paraneoplastic retinopathy
  - Degenerative
    - Mac-tel
    - Retinal dystrophies
    - AMD
  - Vascular
    - Central serous chorioretinopathy

### Labs

Lab	Result
ACE	41 (nm)
Quantiferon Gold	Negative
FTA-Abs	Reactive
RPR	Reactive
HIV Antigen/Antibody	Non reactive
HIV-1 RNA	Not detected

ANCA Panel	
Lab	Result
Myeloperoxidase Abs	<9.0
Antiproteinase 3 Abs	<3.5
C-ANCA	<1:20
P-ANCA	<1:20
Atypical P-ANCA	<1:20

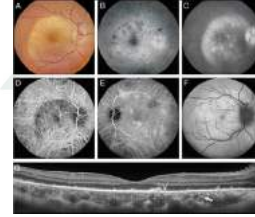
### Additional History

– On further questioning admits to frequent unprotected sexual encounters (men and women)

Diagnosis:  
Acute syphilitic posterior placoid chorioretinitis (ASPPC)

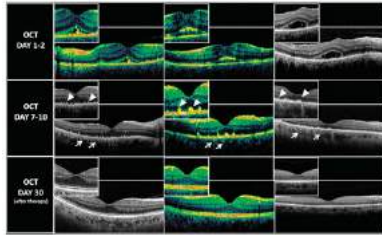
Acute syphilitic posterior placoid chorioretinitis (ASPPC)

- More rare form
- Peripapillary or macular pale yellow-gray subretinal lesions
- +/- underlying fluid
- Specific imaging findings:
  - OCT: EZ disruption with sub-RPE deposits
  - AF: HypERAutofluorescence
  - ICG: early and late hypofluorescence
  - FA: progressive, diffuse leak



OCT in ASPPC

- Early: SRF (43%)
- Later: Loss of IS/OS junction, RPE nodularity/thickening
- Post-treatment: Resolution of IS/OS and RPE changes



Management of ocular syphilis

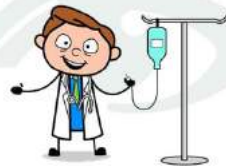

Treat as neurosyphilis w/ 10-14 day treatment course

- Option #1: IV: Aqueous crystalline penicillin G
  - 3-4 million units q4h OR continuous infusion of 18-24 million units qday
- Option #2: IM: Procaine penicillin G 2.4 million units qday AND PO: Probenecid 500mg QID

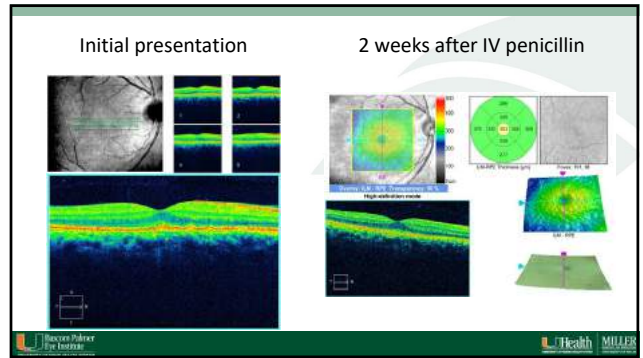
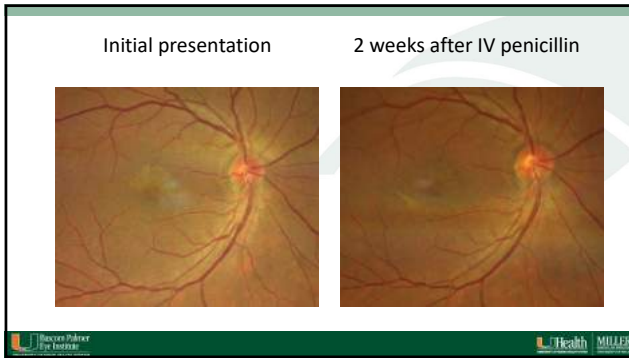
Sent to Jackson

- RPR Titer = 1:1024 at JMHS
- - 3,000,000 units IV penicillin q4h for 7 days, then sent home w/ home health



2 weeks after IV penicillin

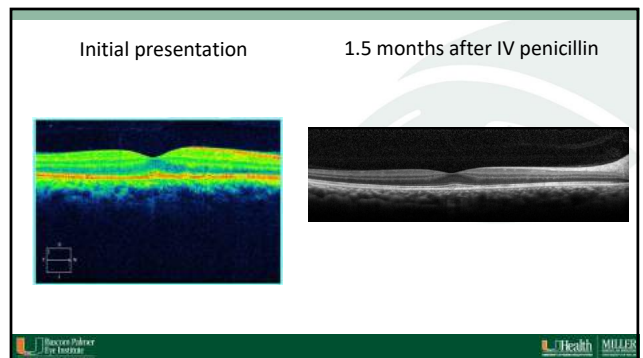
	OD initial	OD @ 2 weeks
BCVA	20/70 +1	20/50
PAM		20/20
Confrontational VFs	Central scotoma	Full
EOMs	Full, ortho	Full, ortho



1.5 months after IV penicillin

	OD initial	OD @ 2 weeks	OD @ 1.5 months
BCVA	20/70 +1	20/50	20/25
PAM	20/20	20/20	20/20
Confrontational VFs	Central scotoma	Full	Full
EOMs	Full, ortho	Full, ortho	Full, ortho

University of Michigan Health System | RUCSOP | Eye Institute | MILLER



- ## Take home points
- Don't forget about syphilis!
  - Look for the classic OCT changes of ASPPC
  - Check for HIV
  - Nontreponemal tests and CSF are used to track response
  - ASPPC has great prognosis if treated appropriately
- University of Michigan Health System | RUCSOP | Eye Institute | MILLER

## References


- Adkins, A. L., et al. (2001). "Ocular syphilis." *Survey of Ophthalmology*, 47(5), 453-461.
- Cantor, A., Nelson, H.D., Diegen, M., et al. Screening for syphilis in Nonpregnant Adolescents and Adults: Systematic Review to Update the 2004 U.S. Preventive Services Task Force Recommendation [Internet]. Rockville (MD): Agency for Healthcare Research and Quality (AHRQ); 2010. (US Preventive Services Task Force Evidence Report/Technology Assessment, No. 136.) Table 2. Sensitivity and Specificity of Commonly Used Syphilis Tests. Available from: <http://www.ncbi.nlm.nih.gov/pmc/articles/PMC3049434/>
- Coq, J.M., et al. (2012). Treatment guidelines. *Journal of Antimicrobial Chemotherapy*. doi:10.1093/acq/ckr220 [Accessed 20 August 2012].
- Davis, D. Ocular syphilis. *Curr Opin Ophthalmol*. 2014;25(8):515-518. doi:10.1097/CIO.0000000000000030
- Fambella, A., Ghahri, S., Hedges, L., et al. Ocular syphilis—back again: understanding recent increases in the incidence of ocular syphilis disease. *Opt Immunol/Ophthalm*. 2005;15(3):207-212. doi:10.1089/OI.200500710709
- Fort, R.C., Chachra, P.R., Abruzzo, D., Smith, B. Anticardiolipin antibodies in patients with rheumatic diseases. *Arthritis Rheum*. 1997;40(7):712-768. doi:10.1002/art.1700200102
- Hwang-Horowitz, A.F., Johnson, R.C. Diagnostic tests for syphilis: New tests and new algorithms. *Neurology Clin Pract*. 2014;4(1):116-122. doi:10.1212/CPD.0000000000000046
- Jung, J., Michael, M.J., Renshaw, S., et al. Imaging Syphilis Lesions. *International Ophthalmology Clinics*. October 2013 | Volume 52 | Issue 4 | p 225-229 doi:10.1089/IO.2013.52.4.225
- Maragani, A., Sankar, U., Gnan, E., Chinnaiyan, A., Rajagopal, M., Chinnaiyan, E. Prognostic value of fundus autofluorescence in the serologic diagnosis of syphilis. *Ch Eye Opt (Amst)*. 2000;13(4):417-421. doi:10.1159/000073747
- Miller, A., Bock, M.C., Wu, J., et al. The laboratory impact of changing syphilis screening from the rapid plasma reagin to a treponemal enzyme immunoassay: a case study from the Greater Toronto Area. *Sex Transm Dis*. 2013;84(3):190-196. doi:10.1097/STD.0b013e3182910761
- Pohl, F., Cappelletti, A.F., Cornoniello, F.P., et al. Spectral domain optical coherence tomography findings in patients with acute syphilitic posterior placoid chorioretinitis. *Retina*. 2014;34(2):373-384. doi:10.1097/RET.0000000000000091
- Rhee, C.P., Johnson, M., Steiner, J., Bress, N. Syphilis and HIV Co-infection in Mississippi: Implications for Control and Prevention. *AIDS Behav*. 2000;24(4):504-508. doi:10.1007/s10465-010-0250-0
- Saldaña-Ramírez, E. Syphilis and HIV co-infection. Epidemiology, treatment and molecular typing of *Treponema pallidum*. *Disinfect*. 2015;4(2):81-76.
- Saha, A.C., Smith, M., Adams, L., et al. Response to therapy following treatment of serologic only syphilis patients with benzathine penicillin. *Clin Infect Dis*. 2013;56(1):420-422. doi:10.1093/cid/cir118
- Threl, E., Brondino, M. Reverse Sequence Screening for Syphilis. *AACC*. <http://www.aacc.org/education/continuing-education/2014/10/16/reverse-sequence-screening-syphilis>. *Pathology*. 2014.
- Winkler, G.D., de Stark, B., Lantieri, M., Nelson, H.D., Subram, V. Penicillin allergy and desensitization in serious infections during pregnancy. *N Engl J Med*. 1995;333:2229-32.

University of Michigan Health System | RUCSOP | Eye Institute | MILLER

# Retina

**Respuesta de la Retinopatía Proliferativa a Panfotocoagulación  
y Tratamiento Anti-angiogénico Demostrado por  
Angiografía con OCT**

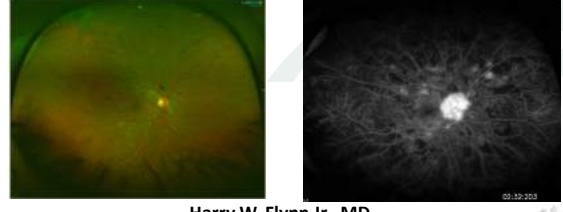
Response of PDR/NVD to PRP and Anti-VEGF as Shown by OCTA



**Dr. Harry W. Flynn, Jr.**

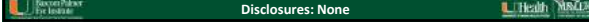**Response of PDR/NVD to PRP/Anti-VEGF on OCTA**

41 year old diabetic man with 20/20 right eye

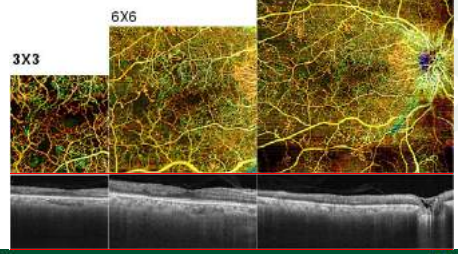


Harry W. Flynn Jr., MD

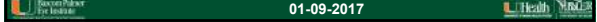
Disclosures: None



**SS-OCTA OD**



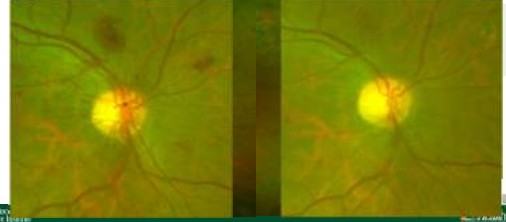
01-09-2017



**Comparison of Optic Disc Photos**

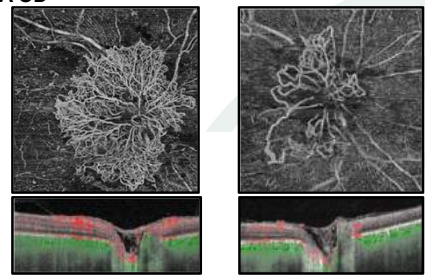
Laser x 4; IVA x 2

01/04/2017 OD VA: 20/20<sup>2</sup>      03/01/2017 OD VA: 20/20<sup>2</sup>



**SS-OCTA OD NVD before and after PRP/anti-VEGF**

VRI

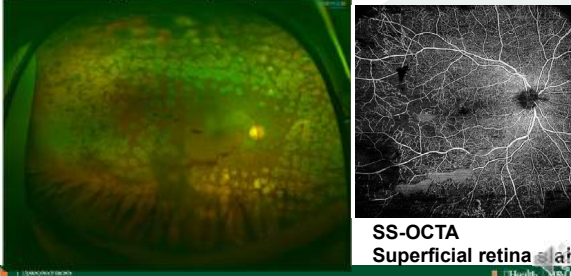


01/04/2017

03/01/2017



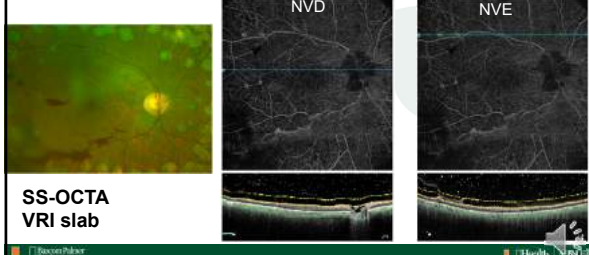
**Followup OD 8/24/2020 VA OD 20/20**



SS-OCTA Superficial retina slab



**Followup OD 8/24/2020 VA OD 20/20**



SS-OCTA VRI slab



1/9/2017

3/1/2017

05-08-2017

8-24-20

### Regression of NVD on OCTA

Thank You!

Rouven Polner Eye Institute

Health MRL

# Retina

**No Estamos Convencidos  
ARN'T Convinced**



**Dr. Luis J. Haddock**

## ARN'T Convinced

Luis J. Haddock  
Assistant Professor of Ophthalmology  
Bascom Palmer Eye Institute

Curso Interamericano 2020

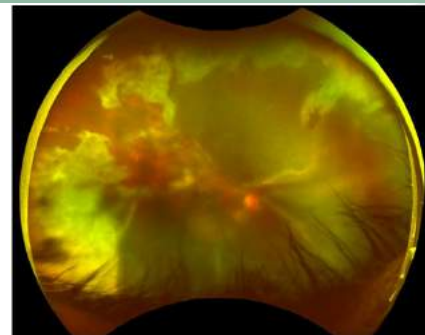
## History of Present Illness

- ❖ 38-year-old male referred to Bascom Palmer with decreased vision OD for 7 months

## Examination

BCVA: → OD: **HM**  
          → OS: 20/20  
Pupils: No APD  
IOP: → OD: 17  
      → OS: 18

	OD	OS
Lids/Lashes	Blepharitis	Blepharitis
Conjunctiva/Sclera	White and quiet	Trace injection
Cornea	Inferior fine KPs	Clear
Anterior Chamber	3+ cell, 1+ flare	Deep and quiet
Iris	Normal	Normal
Lens	Clear	Clear
Vitreous	4+ cell, 2+ haze	Normal

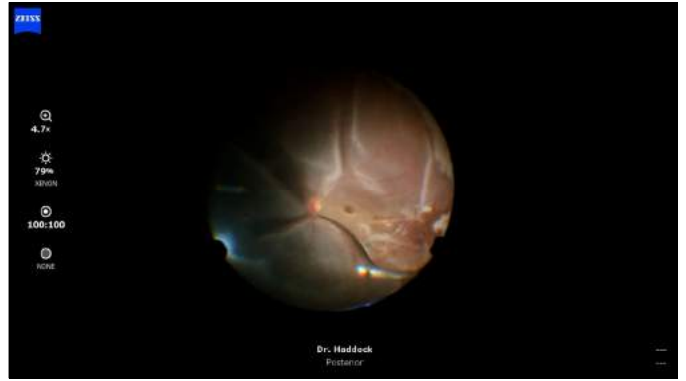

## Differential Diagnosis for Necrotizing Retinopathies

- ❖ Acute Retinal Necrosis
- ❖ Progressive Outer Retinal Necrosis (PORN)
- ❖ Syphilitic Retinitis
- ❖ Toxoplasmosis Retinitis

## Work-up

- ❖ A/C tap → Aqueous PCR testing
- ❖ Laboratory work-up: Toxo IgM/IgG, RPR, HIV, HSV, CMV
- ❖ Continue Bactrim 800-160 PO BID, Valtrex 1g PO TID
- ❖ Proceed with RD Repair




Post-Op Month 1

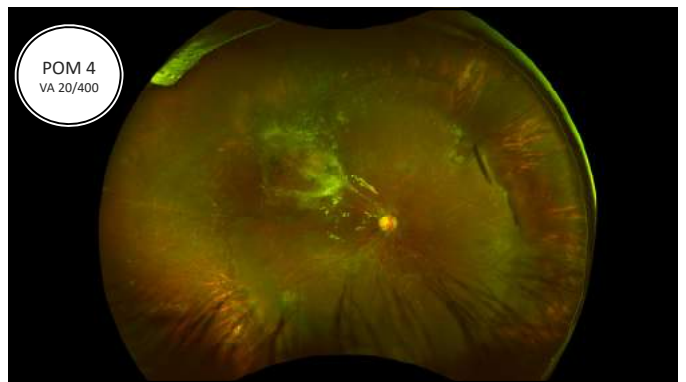
- ❖ Va: 20/800
- ❖ IOP: 15
- ❖ Retina remains

**TOKOPLASMA GONDII DNA, QUALITATIVE REAL-TIME PCR**

Source  
TOKOPLASMA GONDII DNA, PCR



VIT FLUID OD  
DETECTED (A)



Toxoplasma Acute Retinal Necrosis

**Diagnosis and Treatment of Acute Retinal Necrosis**  
*A Report by the American Academy of Ophthalmology*

- ❖ Diagnosis
  - ❖ Historically a clinical diagnosis
    - ❖ Delays can result in poor clinical and visual outcomes
    - ❖ Treatment should be initiated if high suspicion
- ❖ Laboratory methods
  - ❖ Serum/intraocular fluid antibody testing- PCR
  - ❖ Viral culture
  - ❖ Retinal biopsy
- ❖ Treatment
  - ❖ Intravenous antivirals
  - ❖ Oral antivirals
  - ❖ Intravitreal antivirals

1. Pendergast et al. Absence of herpesvirus DNA by polymerase chain reaction in ocular fluids obtained from immunocompetent patients. Retina 2000.

## Take Home Points Diagnosing Toxoplasma ARN

Atypical presentations: Bilateral, extensive, multifocal disease

More commonly reported in immunocompromised patients or elderly patients

Extensive areas of retinal involvement may hide retinal scars and lead to diagnosis of herpetic retinitis

Confirmation and diagnosis made with anterior chamber or vitreous PCR



## Gracias



# Retina

**Cuidado: Puede Suceder Cuando Usted  
Menos lo Espera**

Beware: It Can Happen When You Least Expect It



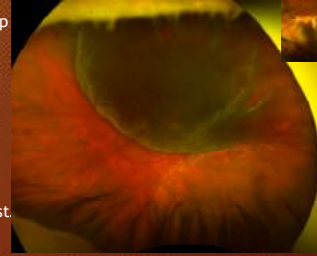**Dr. William E. Smiddy**

# It Can Happen Anytime!

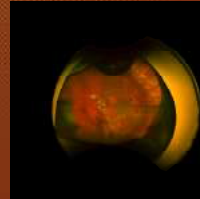
William E. Smiddy, MD

67M with mac off RD, HM, multiple breaks OS; (OD previous mac off RD repair 7 yrs ago, 20/40)

- More chronic inf temp component w demarcation
- Bullous sup RD
- Rec PPV/SBP/FGX
- SB placed, AFX performed, laser underway
- All is well until visibility suddenly lost



Follow-up: 8 mos later, 20/60, reattached



# **Glaucoma**

**Segunda Opinión "¿Necesito una PIO aún más Baja?"**

Second Opinion "Do I Need an Even Lower IOP?"



**Dr. Swarup S. Swaminathan**

## Second Opinion: “Do I need an even lower IOP?”

Swarup S. Swaminathan, MD  
Assistant Professor of Clinical Ophthalmology  
Bascom Palmer Eye Institute

XLII Inter-American Course in Clinical Ophthalmology 2020  
21 November 2020

## Initial Presentation

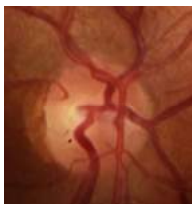- 62 year-old female
- Diagnosed with CACG 5 years prior, s/p LPI OU
- Seeking second opinion regarding worsening vision OS
- “Should my IOP should be lower?”

## Additional History

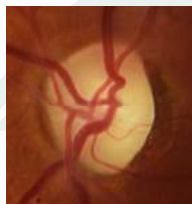- **PMH:** hyperlipidemia, obesity
- **POH:** phaco OU, LPI OU
- **Ocular medications:** none
- **ROS:** negative for prior episodes of eye pain, redness, emesis, headaches, double vision

## Examination

- **VA:** 20/20 | 20/80
- **IOP:** 17 | 17
- **Pupils:** PERRL OU
  - No RAPD
- **Gonioscopy:** SS OU
- **Color plates:** 13/14 | 1/14
- **Pertinent Exam Findings**
  - *K:* Clear OU
  - *AC:* d/q OU
  - *Iris:* patent PI OU
  - *Lens:* PCIOL OU



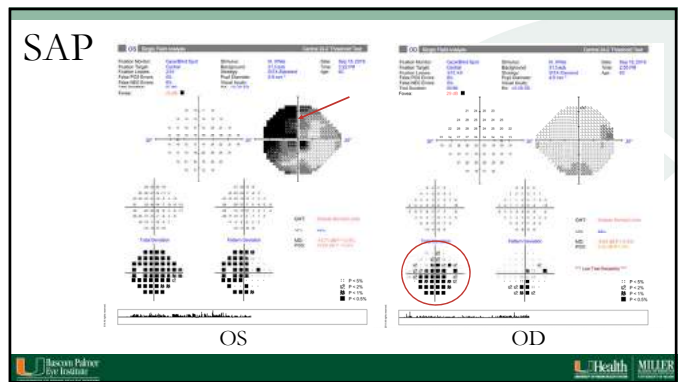
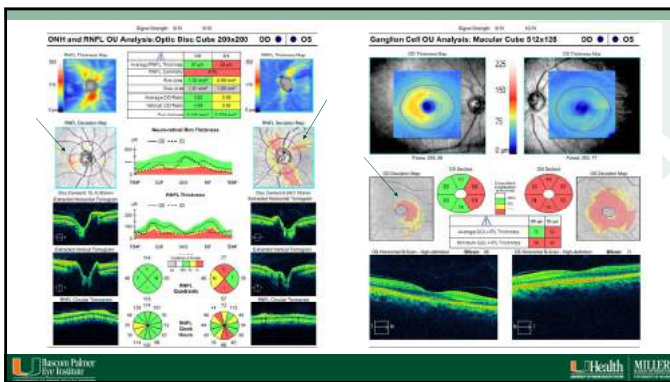
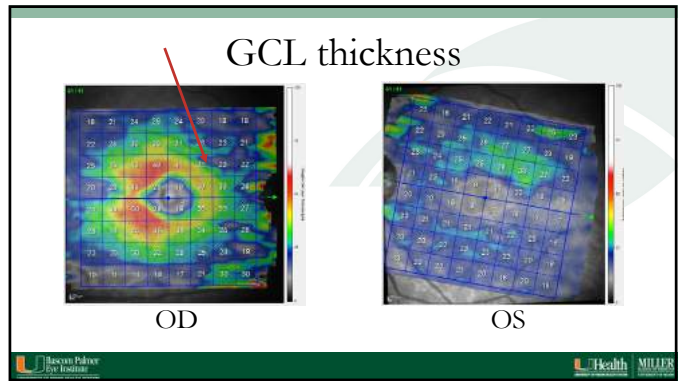
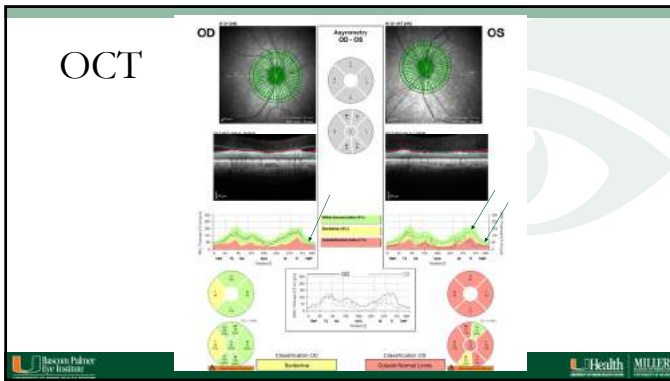
OD  
C/D 0.4



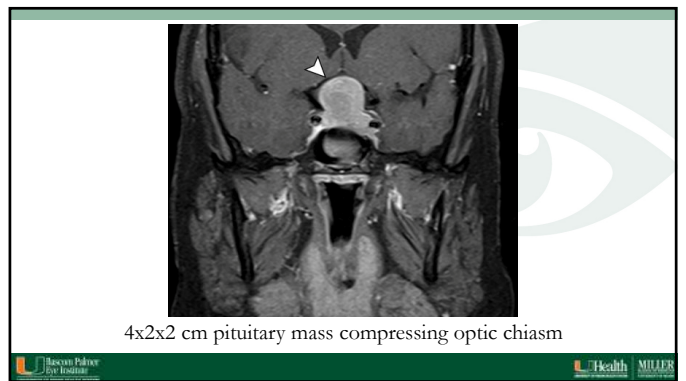
OS  
C/D 0.7

## Additional history

- Does not recall IOP >20 mmHg
- No prior history of:
  - Trauma
  - Uveitis
  - Raynaud’s syndrome, migraines, hypotension



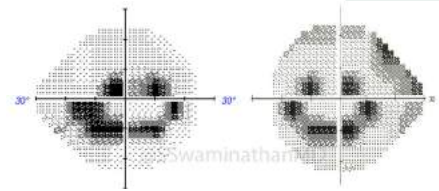
- ## Next Steps?
- Patient advised that IOP likely is okay
  - Referred to neuro-ophthalmology clinic for further evaluation
  - Patient received MRI Brain + Orbits



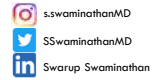
## When to refer to neuro-ophthalmology?

- Young age
- IOP WNL
- Loss of color vision
- ON pallor > cupping
- SAP findings: hemianopia / quadrantanopia
  - Respecting vertical midline
- **OCT findings**
  - Prominent temporal loss on RNFL
  - Nasal loss on GCL/GCIPL

*Not all patients in glaucoma clinic have glaucoma!*



Thank you!  
sswaminathan@miami.edu



# **Glaucoma**

## **Caso Misterioso de Hipotonía** **Mysterious Case of Hypotony**



**Dr. Paul F. Palmberg**

## Mysterious Case of Hypotony

Curso Interamericano 21 de Noviembre, 2020  
Ann Quan, MD, and Paul Palmberg, MD, PhD  
Bascom Palmer Eye Institute



### In the beginning....

- 70 y/o Argentinian man with controlled POAG years after a trab underwent a 26g PPV for a peripheral rhegmatogenous RD.
- Post-operatively the patient had hypotony and low serous choroidal detachments. They were observed for a month, then we were called.
- The IOP was 3 mm Hg, Va 20/50, AC deep and quiet, no RD on dilated fundus exam or B-scan ultrasonography. No cyclodialysis cleft on gonio, nor on anterior segment UBM.
- We observed out to 3 months, without resolution, and he began to get corneal edema and flattening of the bleb.
- WHAT WOULD YOU DO NOW?

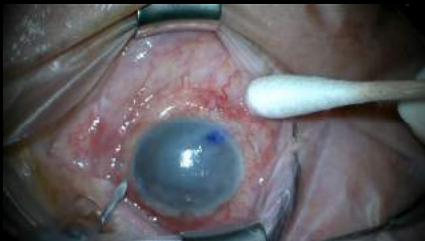

- We drained the serous choroidal detachments.
- To deal with the expected IOP spike and apparently failed trab?
- We placed a prolene-ligated Ahmed Implant
- But, the IOP did NOT rise as had been expected.
- What now?



### On the way to the OR....

- My thought was that the patient probably had a cyclodialysis cleft created by the trocar of the 26g vitrectomy.
- I planned to use an endo probe to view the angle and find the cleft.
- I happened to discuss the case with Dr. Ta Chen "Peter" Chang, who mentioned seeing such a case in which the cleft was behind the iris!
- At surgery, we could NOT find a cleft in the angle.
- We inflated the sulcus with viscoelastic, and searched for the cleft with a the illuminated endo probe...saw two suspicious areas, corresponding to where trocars had been used in the PPV.



Using double flap modification of the technique of Kuchle M, Naumann GOH. Direct cycloplexy for traumatic cyclodialysis with persisting hypotony; report in 29 consecutive patients. Ophthalmology 1995; 102: 322-233



### Key Points

- Sort out the problems: glaucoma, hypotony, choroidals
- Provide a solution for all of them
  - Choroidals drained could mean pressure spike if bleb failed, need alternative means of controlling IOP, but adjustable, once the choroidals are gone, thus the prolene-ligated (on the AC portion of the tube) Ahmed Glaucoma Implant
    - When that failed, and bleb failed and cornea clouding, needed to assess for hidden cleft, presumably from the PPV trocars.
    - Endo probe a big help, with viscoelastic to widen angle
    - When no cleft in angle, viscoelastic used to widen the sulcus
    - 2-scleral flap technique to explore for cleft, using fluorescein-BSS
    - After closing cleft and inflating eye, IOP held, so time to cut the prolene on the AGI to control the IOP
    - Final point, listen to your junior colleagues



# **Glaucoma**

**Ojos Pequeños, “Soluciones Grandes”**  
Little Eyes, “Big Solutions”

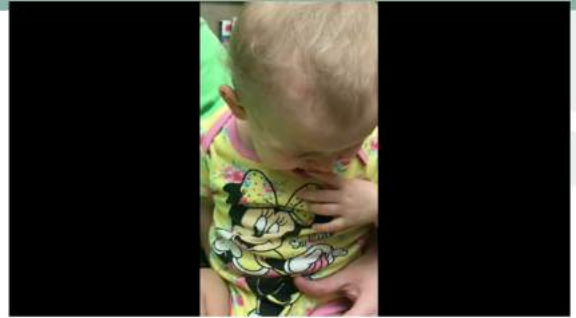

**Dr. Elena Bitrian**

# Ojos Pequeños, Soluciones Grandes

Elena Bitrian, MD

The Samuel & Ethel Balkan International Pediatric  
Glaucoma Center



## Presentación Clínica

Niña 10 meses de edad

Fotofobia, blefarospasmo y lagrimeo

Cirugía de glaucoma a los 3 meses de edad

Dorzolamida-timolol 2 veces/día



## Examen Bajo Anestesia

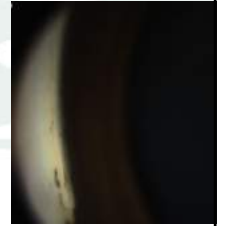
PIO 35/32 mmHg

Diam corneal 13x 12.5/13x 12.25

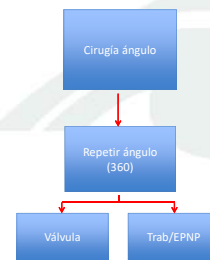
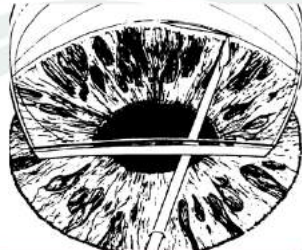
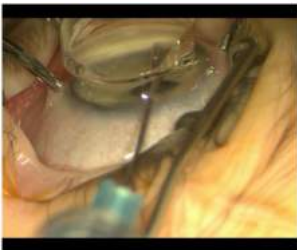LA 21.8/21.0 mm

Gonio: 4 horas goniotomía nasal AO

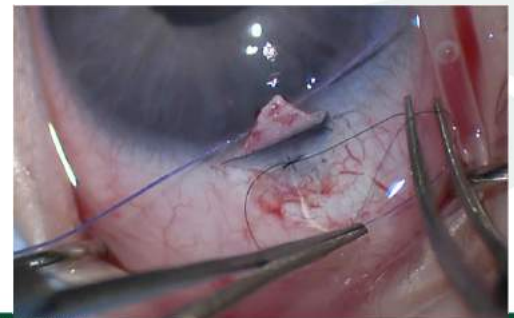
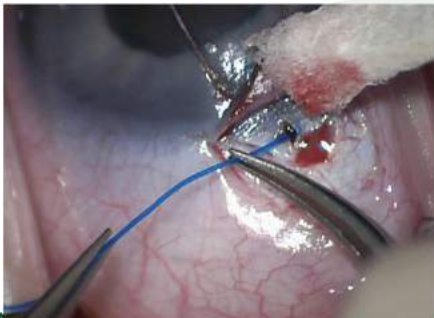
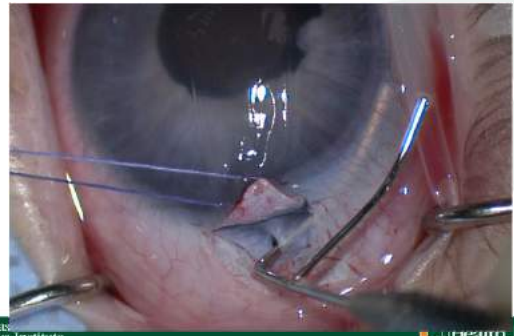
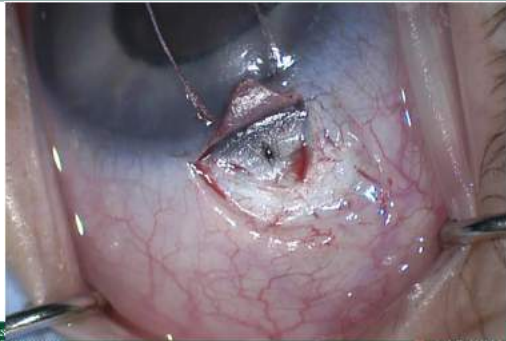
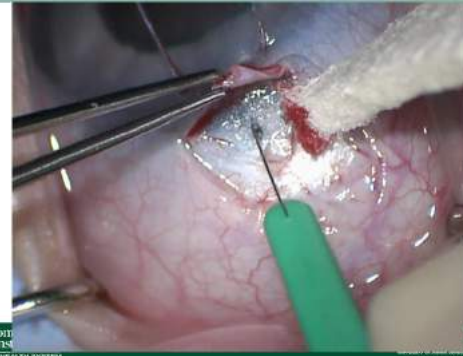
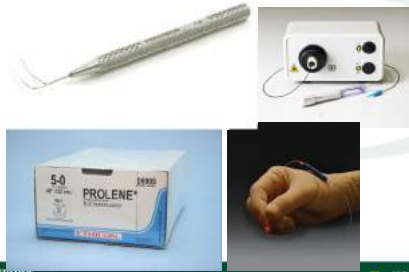Excavación: 0.7 AO

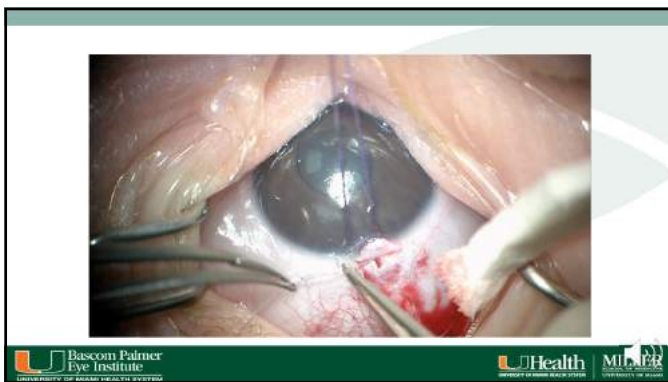
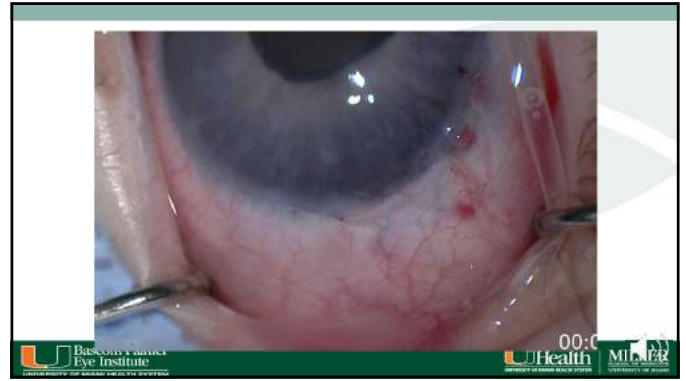
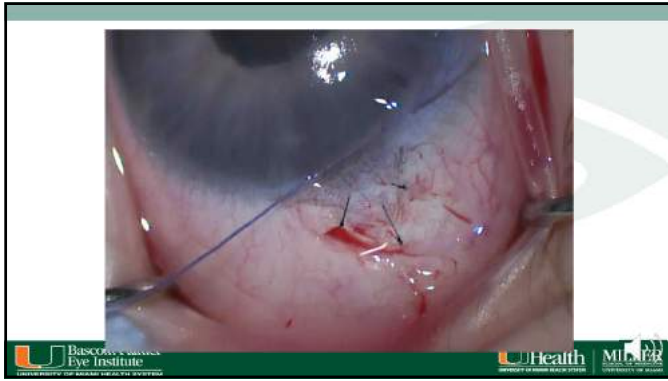
## GONIOTOMÍA



TRABECULOTOMÍA AB EXTERNO





### Conclusiones

- Cirugía angular es cirugía de elección en glaucoma primario congénito
- Considerar repetir cirugía angular antes de cirugía filtrante
- Tratar máximo de ángulo posible (360)
- Individualizar casos para tratamiento

Bascom Palmer Eye Institute  
UNIVERSITY OF MIAMI HEALTH SYSTEM

UHealth  
UNIVERSITY OF MIAMI HEALTH SYSTEM

MILAMER  
UNIVERSITY OF MIAMI



Bascom Palmer Eye Institute  
UNIVERSITY OF MIAMI HEALTH SYSTEM

GABRIEL & EVEL BALCAN  
INTERNATIONAL PEDIATRIC  
GLAUCOMA CENTER

UNIVERSITY OF MIAMI  
UNIVERSITY OF MIAMI

### CHILDHOOD GLAUCOMA RESEARCH NETWORK

[elenabitrian@miami.edu](mailto:elenabitrian@miami.edu)  
[abroad@miami.edu](mailto:abroad@miami.edu)

Bascom Palmer Eye Institute  
UNIVERSITY OF MIAMI HEALTH SYSTEM

UHealth  
UNIVERSITY OF MIAMI HEALTH SYSTEM

MILAMER  
UNIVERSITY OF MIAMI

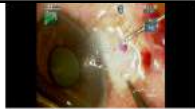# **Glaucoma**

**Lo que he Aprendido Usando el  
Microshunt Durante 10 años**

**What I Have Learned Using the  
Microshunt for 10 Years**



**Dr. Juan Batlle**



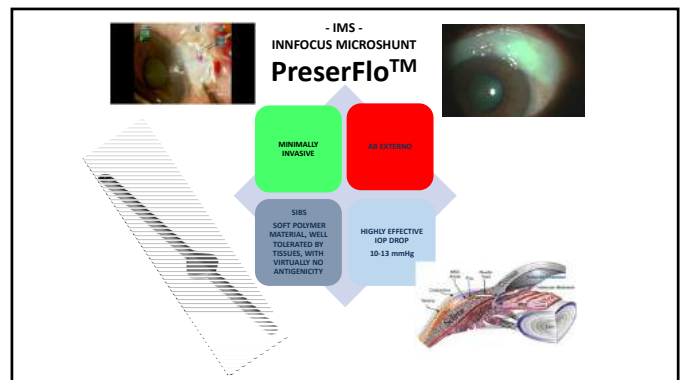
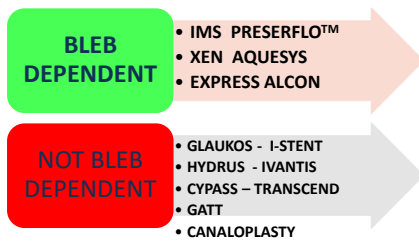
# PRESERFLO™ MICROSHUNT WHERE ARE WE IN 2020?

DR. JUAN F. BATLLE  
CHIEF OF OPHTHALMOLOGY AT  
HOSPITAL DR. ELÍAS SANTANA  
MEDICAL DIRECTOR OF CENTRO LASER IN SANTO DOMINGO  
PAST CHAIRMAN FOR BLINDNESS PREVENTION  
IAPB LATIN AMERICAN REGION

## FINANCIAL DISCLOSURES

- DR. BATLLE IS A PAID CONSULTANT FOR INNFOCUS AND SANTEN IN THE DEVELOPMENT OF THE PRESERFLO™ MICROSHUNT TECHNOLOGY IN COLLABORATION WITH SANTEN AND THE BASCOM PALMER EYE INSTITUTE.

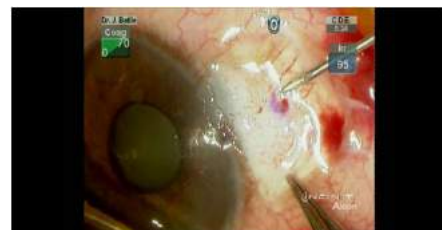### SIMPLE CLASSIFICATION OF THE NEW DEVICES



## WHERE IS IT PLACED AND HOW?

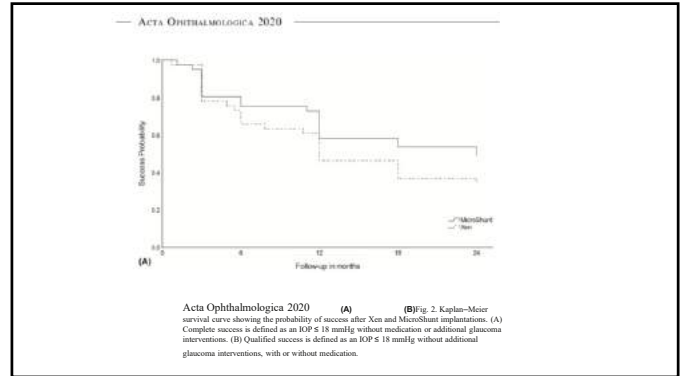
TOPICAL SUBCONJUNCTIVAL ANESTHESIA  
PREFERRABLY SUPEROTEMPORAL  
AB EXTERNO  
SUB-TENON'S  
NO VISCOELASTIC  
CAN BE USED IN COMBINATION WITH PHACO

## AB EXTERNO INSERTION OF IMS TUBE

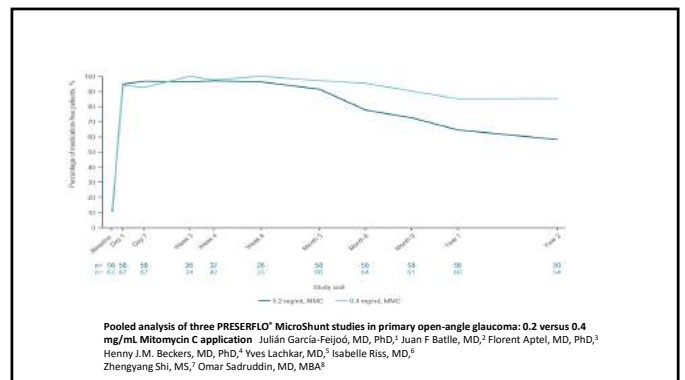




HOW DOES IT COMPARE TO XEN?  
THE DUTCH LOOKED AT IT



DOES THE CONCENTRATION OF THE MITOMYCIN C REALLY MATTER?  
COLLABORATIVE STUDY SAYS YES



HOW IS THE FDA STUDY GOING?

DR. PAUL PALMBERG KNOWS  
DOUBLE MASKED COMPARISON OF  
TRABECULECTOMY VS PRESERFLO™  
WITH MITOMYCIN C

THANK YOU!



# **Cirugía de Cataratas/Refractiva** **Cataract/Refractive Surgery**

## **Cirugía de Cataratas en la Ausencia de Soporte Zonular**

Cataract Surgery in the Absence  
of Zonular Support



**Dr. Sonia H. Yoo**

## Cataract Surgery in the Absence of Zonular Support

Sonia H. Yoo, MD  
Neel Pasricha, MD

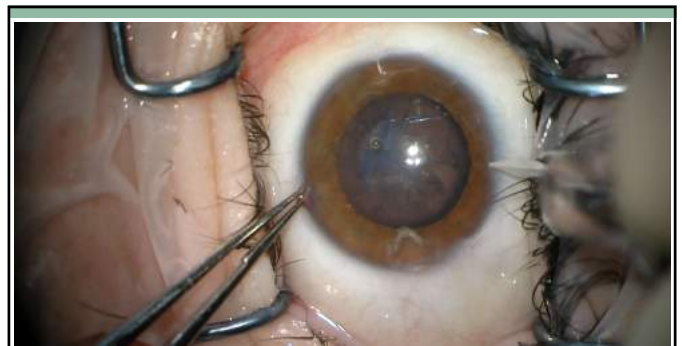

No Relevant Financial Disclosures



## 17 yo monocular male, ROP

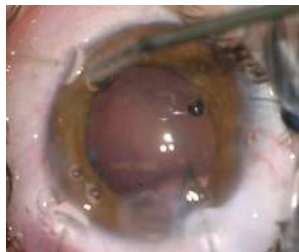	OD	OS
VAcc	LP	20/250 eccentric*
PUPILS	Non-reactive, None by reverse	Reactive
IOP	35	18
EOM	Full, Nystagmus	Full, Nystagmus
CVF	Complete defect	Full

\*BCVA 20/200 prior to cataract



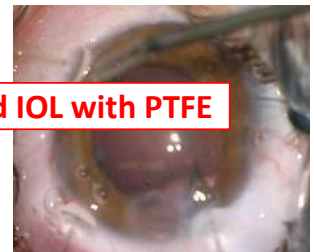## Compromised Capsular Support

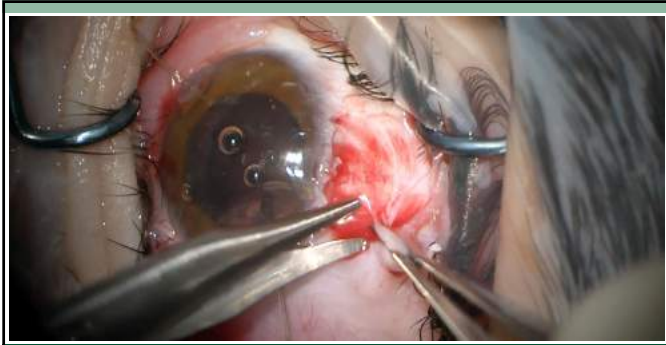
1. Cionni CTR
2. Ahmed CTS + CTR
3. ACIOL
4. Iris-claw IOL (AC or PC)
5. Iris-sutured IOL
6. Yamane ISHF
7. Glued ISHF
8. Scleral-sutured IOL



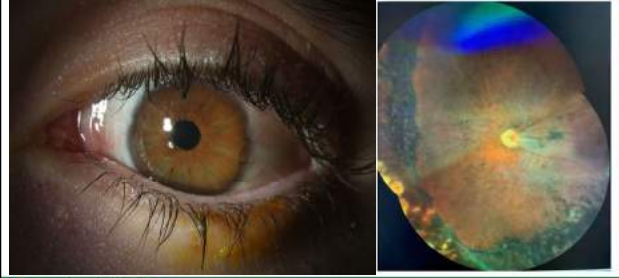## Compromised Capsular Support

1. Cionni CTR
2. Ahmed CTS + CTR
3. ACIOL
4. Iris-sutured IOL
5. Scleral-sutured IOL with PTFE
6. Yamane ISHF
7. Glued ISHF
8. Scleral-sutured IOL





6 wks postop 20/100



**Cirugía de Cataratas/Refractiva**  
**Cataract/Refractive Surgery**

**Queratomileusis para Corneas Anormales**  
**Keratomileusis for Abnormal Corneas**






**Dr. Rahul S. Tonk**

XLII Inter-American Course in Clinical Ophthalmology  
Saturday November 21, 2020

## Keratomileusis for Abnormal Corneas

**Rahul S. Tonk, MD, MBA**  
Assistant Professor of Ophthalmology  
Cornea, Cataract, and Refractive Surgery  
Bascom Palmer Eye Institute

## Disclosures



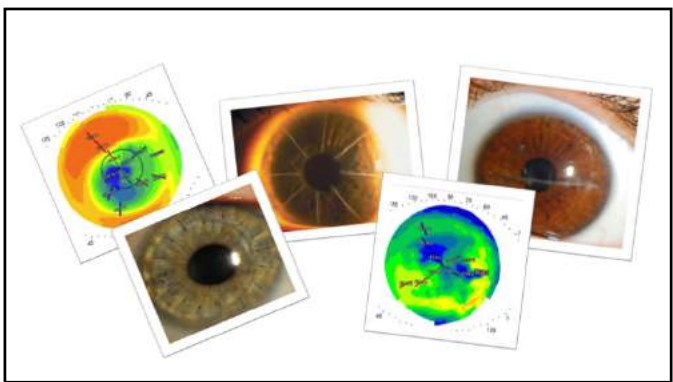
Financial support: None  
Conflicts of Interest: None

ker · a · to · mi · leu · sis

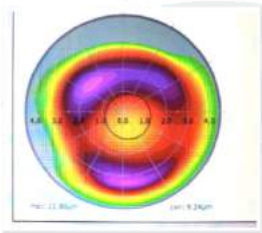



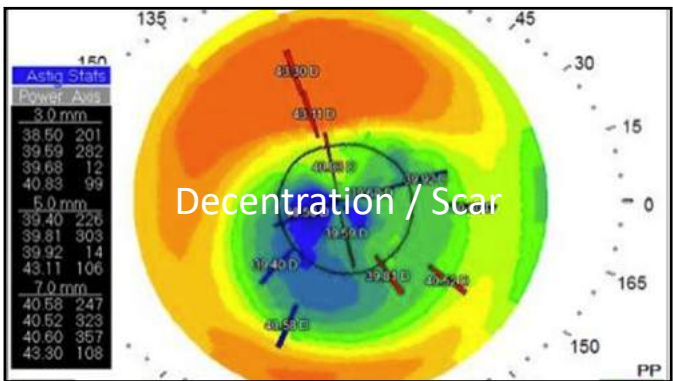
/ ,kerədōmī 'lōʊsəs /

From Greek κέρας (kéras: horn) and αμίλευσις (smileusis: carving)

Surgical reshaping of the cornea



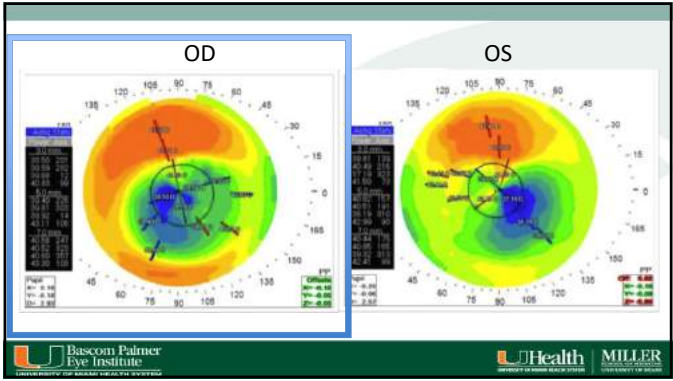
### Topography-Guided Ablation

**Manifest Refraction**

	Sphere	Cylinder	Axis	Dist VA	Add	Near VA
Right	-2.50	+0.50	140	20/30	+2.50	J1+
Left	-3.25	+1.25	040	20/25	+2.50	J1+

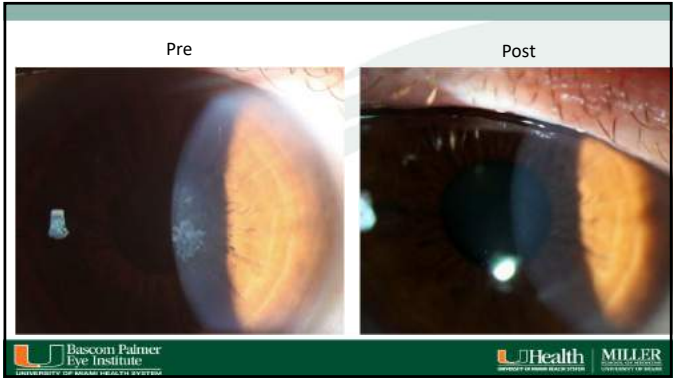
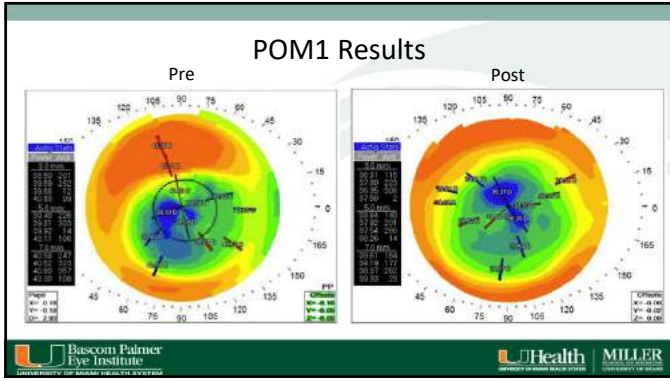
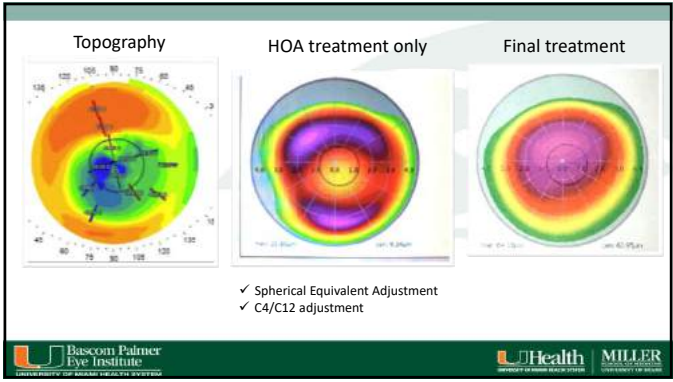
OD

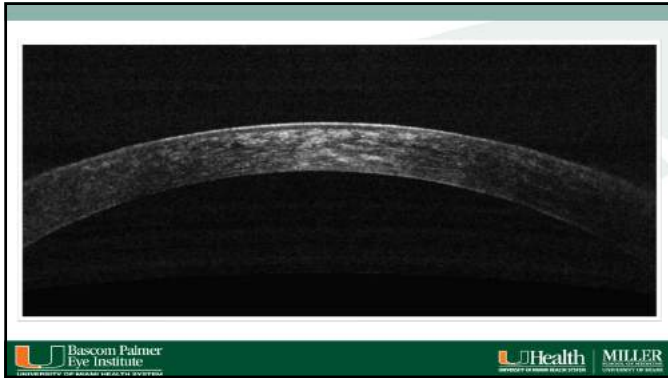

✓ Adequate corneal thickness  
✓ Not ectasia

Bascom Palmer Eye Institute  
UNIVERSITY OF MIAMI HEALTH SYSTEM

UHealth MILLER  
UNIVERSITY OF MIAMI





## Results

- UCVA 20/200 → 20/40
- Manifest refraction  
 PRE-OP: -2.50 +0.50 x140 20/30-  
 POM1: **-0.75 +0.50 x30** 20/20-2
- Subjective improvement in quality

## References

- Wen D1, Song B1, Li Q1, Tu R1, Huang Y1, Wang Q1,2, McAlinden C1,3, O'Brart D4,5, Huang J1,2. Comparison of Epithelium-Off Versus Trans-epithelial Corneal Collagen Cross-Linking for Keratoconus: A Systematic Review and Meta-Analysis. *Cornea*. 2018 Aug;37(8):1018-1024. doi: 10.1097/ICO.00000000000021632
- Kanelopoulos AJ, Ajuetelli G. Epithelial remodeling after partial topography-guided normalization and high-fluence short-duration crosslinking (Athens protocol): results up to 1 year. *J Cataract Refract Surg*. 2014;40(10):1597-602. doi: 10.1016/j.jcrs.2014.02.03.
- Anastasio John Kanelopoulos, MD, George Ajuetelli, PhD. Keratoconus Management: Long-Term Stability of Topography-Guided Normalization With High-Fluence CXL Stabilization [The Athens Protocol]. *Journal of Refractive Surgery*. 2014;30(2):88-92 <https://doi.org/10.3928/1081597X-20140120-03>
- Bardan AS, Lee H, Nanavaty MA. Outcomes of Simultaneous and Sequential Cross-linking With Excimer Laser Surface Ablation in Keratoconus. *J Refract Surg*. 2018;34(10):690-696. doi: 10.3928/1081597X-20180824-01.
- Reinstein DZ, Archer TJ, Gobbe M. Combined corneal topography and corneal wavefront data in the treatment of corneal irregularity and refractive error in LASIK or PRK using the Carl Zeiss Meditec MEL80 and CR2 Wulfer. *J Refract Surg* 2009;25:503-515.
- Reinstein DZ, Yoon C, Carp GJ, Archer TJ, Gobbe M, Miller EA. Optical zone enlargement and recenteration after previous myopic LASIK using topography-guided custom ablation. ESCRS 2015. Barcelona, Spain, 2015.
- Reinstein DZ, Archer TJ, Gobbe M. Rate of change of curvature of the corneal stromal surface drives epithelial compensatory changes and remodeling. *J Refract Surg* 2014;30:800-802.
- Vinciguerra P, Roberts CJ, Albe E, Romano MR, Mahmoud A, Trazza S, Vinciguerra R. Corneal curvature gradient map: A new corneal topography map to predict the corneal healing process. *J Refract Surg* 2014;30:202-207.
- Reinstein DZ, Archer TJ, Gobbe M. Improved effectiveness of trans-epithelial phototherapeutic keratectomy versus topography-guided ablation degraded by epithelial compensation on irregular stromal surfaces [plus video]. *J Refract Surg* 2013;29:526-533.
- Reinstein DZ, Archer TJ, Dickson ZL, Gobbe M. Trans-epithelial phototherapeutic keratectomy protocol for treating irregular astigmatism based population on epithelial thickness measurements by Artemis very high-frequency digital ultrasound. *J Refract Surg* 2014;30:380-387.
- Reinstein DZ, Gobbe M, Archer TJ, Yousefi G, Sutton HF. Stromal surface topography-guided custom ablation as a repair tool for corneal irregular astigmatism. *J Refract Surg* 2015;31:54-59.
- Vinciguerra P, Camesasca F. Custom phototherapeutic keratectomy with intraoperative topography. *J Refract Surg* 2004;20:555-563.

# **Cirugía de Cataratas/Refractiva** **Cataract/Refractive Surgery**

**Manejo de Cataratas Blancas**  
Management of White Cataracts



**Dr. Florence Cabot**

## Management of white cataracts

Florence Cabot, MD

Assistant Professor of Clinical Ophthalmology  
Cornea, Cataract & Refractive Surgery  
Bascom Palmer Eye Institute  
University of Miami Miller School of Medicine

## Financial Disclosure & Conflicts of Interest

None

## Preop evaluation

- Etiology: trauma, steroids, DM2....
- Zonular status
- Discussion with patient :
  - Higher risk of intraop/postop complications
  - Longer recovery
- Reliability of IOL measurements – aim myopic

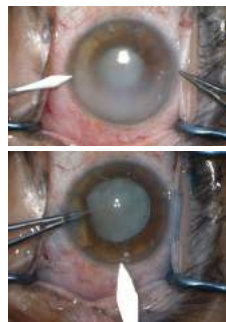
## Anesthesia

- If retrobulbar/peribulbar anesthesia, use Honan balloon to diffuse anesthetic
- Loosen lid speculum
- 250cc of 20% mannitol IV 30 min before surgery



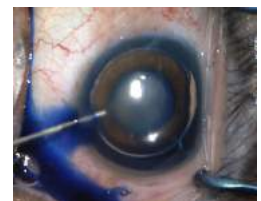
## Incisions

- 1 or 2 paracentesis prior to main incision
- Injection of viscoelastic – soft shell technique prior to main incision
- Pressure balance between bag and AC



## Manual Capsulotomy

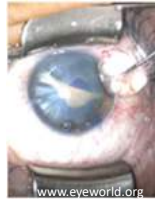- Trypan blue
  - If zonular loss, posterior capsule may also be stained
  - Can consider applying trypan blue under viscoelastic for more controlled staining





## Manual Capsulotomy

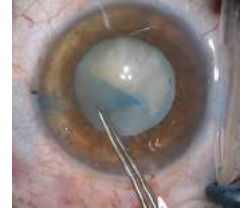- Maintain control during capsulorrhexis by keeping pressure in AC higher than capsular bag (using viscoelastic)
- Puncture anterior capsule with 30-gauge needle
- Aspirate fluidified cortex to decrease intracapsular pressure and avoid Argentinian flag
- Double rhexis
- Large capsulorrhexis



www.eyeworld.org

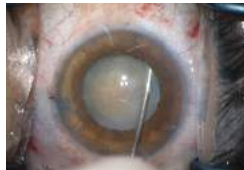## Femto capsulotomy

- Look for tags
- Might be incomplete if intumescent – projection of debris in AC prevent FS Laser from cutting properly the capsule – decrease FS laser energy
- Gentle injection of air and trypan
- Small pupil - ring



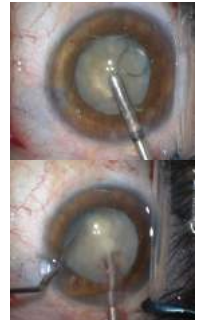
## Hydrodissection

- Gentle
- Sometimes just aspirating the fluidified cortex allows easy rotation of nucleus without hydrodissection
- Risk of posterior capsule blow out



## Phaco techniques

- Adjust phaco settings
- Avoid heat build-up at the incision (wound burn)
- Re-protect the corneal endothelium with additional application of viscoelastic during the surgery
- MSICS vs phaco vs mechanical snare
- Phaco chop: primary, stop and chop, vertical, submarine, central pit - posterior plate
- Usually FS Laser is not able to soften lens



Thank you !

# **Cirugía de Cataratas/Refractiva** **Cataract/Refractive Surgery**

## **Cirugía de Cataratas en una Cámara** **Anterior Estrecha**

Cataract Surgery in a Narrow Anterior Chamber




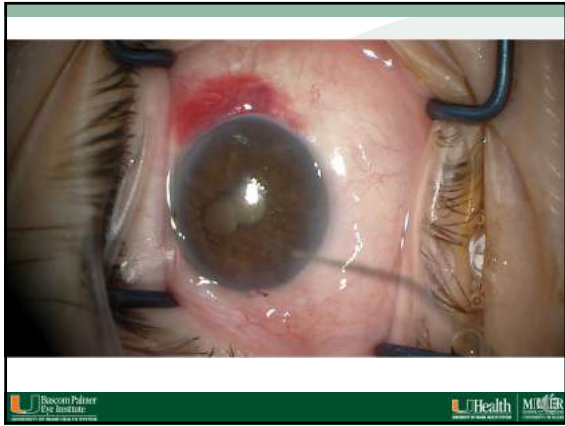

**Dr. William W. Culbertson**

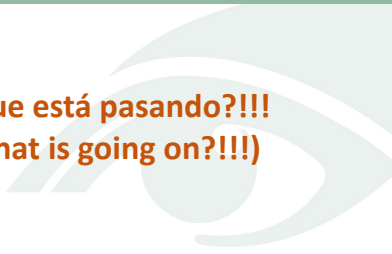



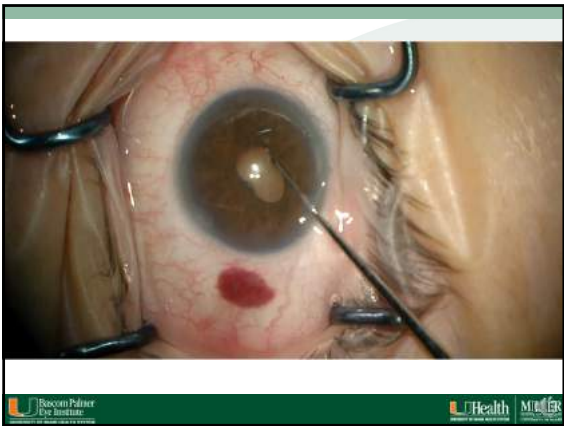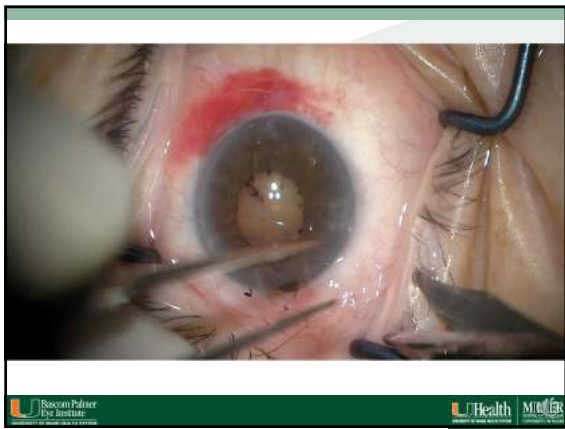
**Cataract Surgery in a Shallow Anterior Chamber**

**William W. Culbertson, MD; Melina I. Morkin, MD,**  
 Bascom Palmer Eye Institute, University of Miami Miller School of  
 Medicine, Miami, FL

**Curso Interamericano**  
 November 21, 2020


**¿ Que está pasando?!!!**  
**(What is going on?!!!)**




**Postoperative Outcomes - POM1**

VA 20/20-2 J2      IOP 19

		Manifest Refraction					
		Sphere	Cylinder	Axis	Dist VA	Axis	1st
Right	-0.50	+0.50	040	20/20	+2.75	20/20	
Left	Plano	+0.50	110	20/25+2	+3.75	20/20	

20/30-2 -> PH 20/25 J7      IOP 21

**OD      OS**

## Conclusions

- Cataract surgery with extremely shallow anterior chamber remains a complex and challenging surgical procedure.
- Microincision vitrectomy surgery (MIVS) may provide an ideal treatment option as it offers an effective and safe method to deepen the anterior chamber. Additionally, IOP and need for glaucoma medications postoperatively seems to be reduced in secondary glaucoma patients.
- The amount of vitrectomy is adjusted according to the anterior chamber depth needed to perform a safe cataract surgery.
- It is important to maintain the tip of the vitrector in the pupillary axis under constant visualization, if possible.


# **Cirugía de Cataratas/Refractiva** **Cataract/Refractive Surgery**

## **Impacto del Astigmatismo Irregular** **en la Cirugía de Cataratas**

Impact of Irregular Astigmatism on  
Cataract Surgery



**Dr. Kendall E. Donaldson**



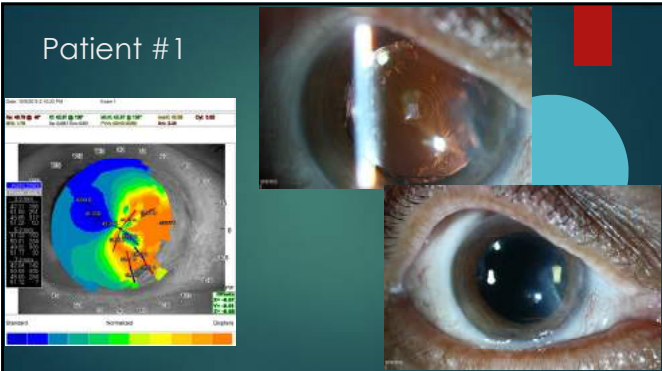
# The Impact of Irregular Astigmatism on Cataract Surgery

KENDALL E. DONALDSON, M.D., M.S.  
 PROFESSOR OF CLINICAL OPHTHALMOLOGY  
 CORNEA/EXTERNAL DISEASE/CATARACT/REFRACTIVE SURGERY  
 MEDICAL DIRECTOR BASCOM PALMER PLANTATION

## Financial Disclosures

- Alcon
- Allergan
- Bausch and Lomb
- Johnson and Johnson
- Omeros
- SUN
- Novartis
- Kala Pharmaceuticals
- Eyevance
- Science Based Health
- Omeros
- Lumenis
- Zeiss

### Patient #1



Topographic map showing irregular astigmatism. Clinical photos show the eye before and after surgery.

### Patient #2

Not happy with the idea of a scleral contact lens



Topographic map showing irregular astigmatism. Clinical photo shows the eye after surgery.

### Patient #3

Not happy with quality of vision with her multifocal IOL...



Clinical photos showing the eye after multifocal IOL implantation.

### Patient #4

Not happy with worsened astigmatism after his multifocal IOL implant, right eye

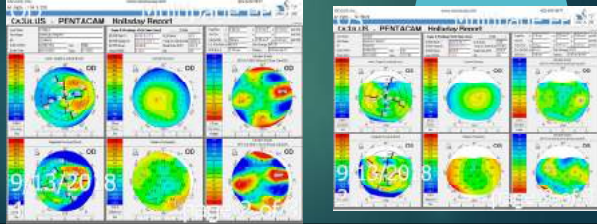
78 year old man who underwent cataract surgery 3 weeks prior with a femto/Tecnis 3.25(ZLB00)/LRI OD (paired with incision)

- Reports worsened vision OD after surgery
- Unable to drive; wife's caregiver
- Hx of mild ERM OD
- BCVA
  - OD: 20/60
  - OS 20/70
- Refraction
  - OD: -0.50 +2.50 x 30 → 20/50-2
  - OS: -1.25 +1.00 x 180 → 20/60

### Patient #4

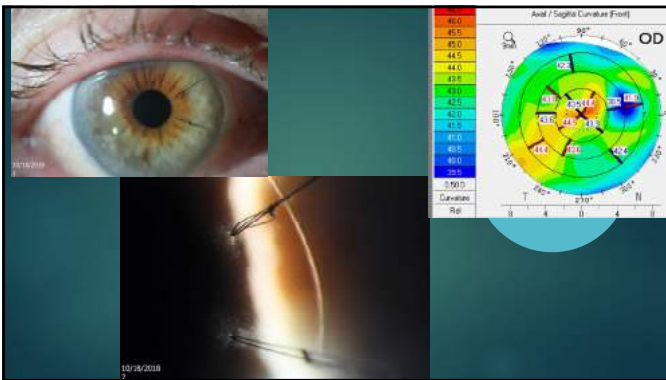
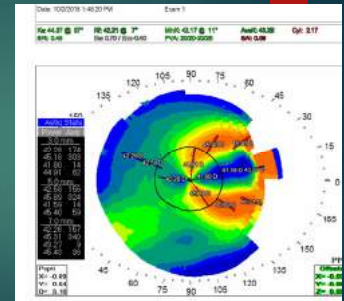
Not happy with worsened astigmatism after his multifocal IOL implant, right eye

Converted regular against the rule astigmatism to irregular astigmatism



### Options

- ▶ LASIK/PRK?
- ▶ IOL exchange
- ▶ Corneal Suture
- ▶ Scleral contact lens
- ▶ Other?

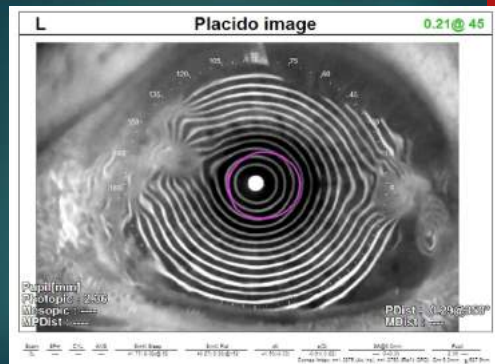
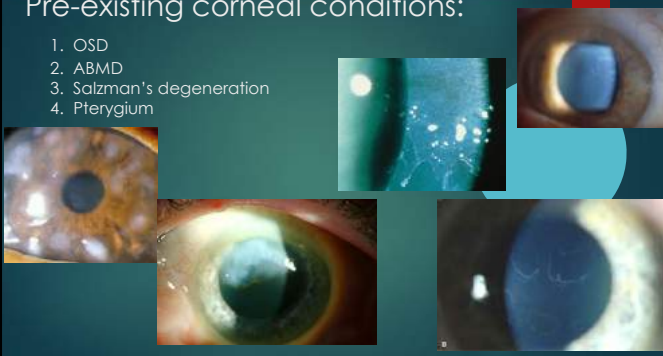

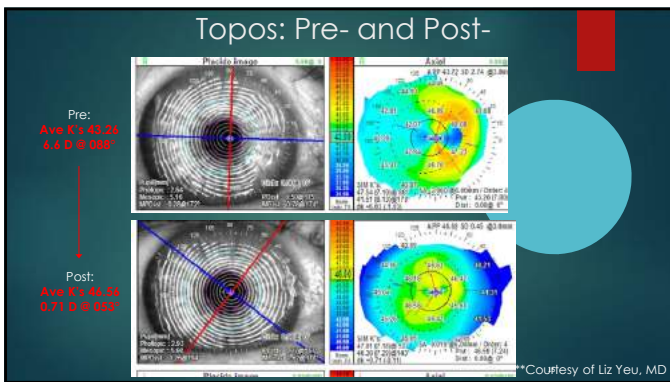
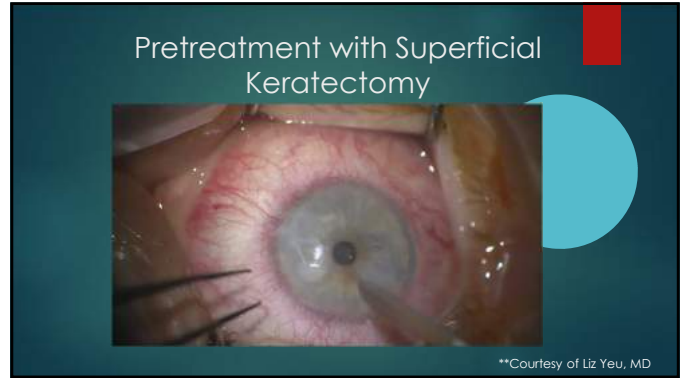
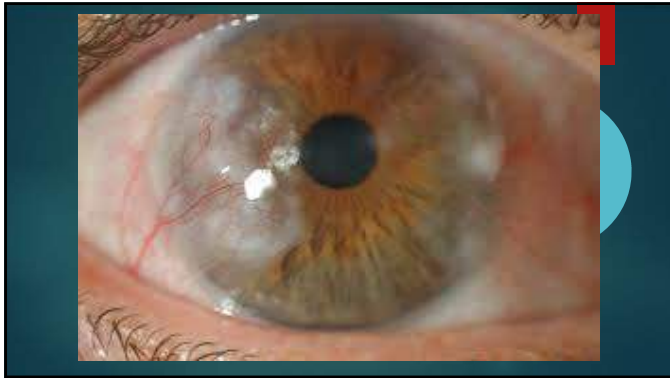### Challenging cases of astigmatism management during cataract surgery...

1. Pre-existing corneal conditions
  - OSD
  - ABMD
  - Salzmann's degeneration
  - Pterygium
2. Keratoconus
3. History of PK
4. History of Corneal Refractive Surgery (RK, PRK, LASIK)

### Pre-existing corneal conditions:

1. OSD
2. ABMD
3. Salzmann's degeneration
4. Pterygium





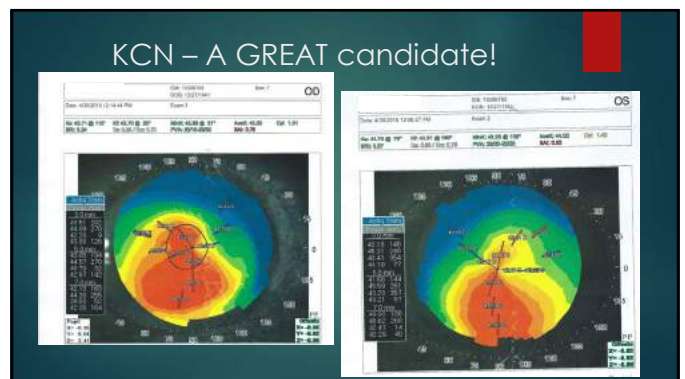
### Keratoconus

When do you use toric IOLs in KCN patients?

1. Mostly regular astigmatism
2. Significant improvement with refraction
3. Able to wear glasses with SOME improvement SOME of the time
4. Stable Ks (despite worsening myopic shift)
5. Reasonable expectations/Good understanding

### KCN – Toric IOL

- ▶ 73 year old female presents for cat eval OS
  - ▶ Hx of KCN and wears RGP with declining vision
- ▶ UCVA
  - ▶ OD: 20/800 20/60 with RGP
  - ▶ OS: 20/1000 20/80 with RGP
- ▶ MRx
  - ▶ OD: -10.50 +4.50 x 90 → 20/40
  - ▶ OS: -13.00 +6.00 x 95 → 20/50




### Outcome

- ▶ OD:
  - ▶ UCVA: 20/30
  - ▶ BCVA: -1.00 + 1.25 x 90 20/25
- ▶ OS:
  - ▶ UCVA: 20/40
  - ▶ BCVA: -1.75 + 1.75 x 100 20/30

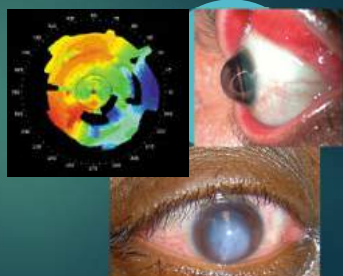


### Keratoconus

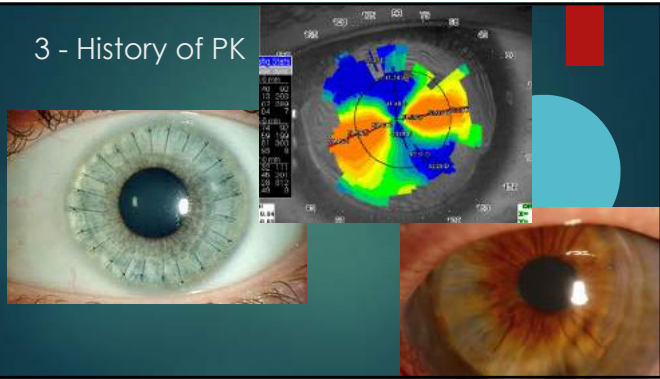
Good Candidate



Bad Candidate



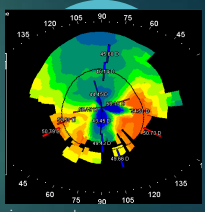
### 3 - History of PK



### Post PK


#### What are we looking for?

- ▶ Try to have all sutures removed before CE/IOL
- ▶ Residual stable REGULAR ASTIGMATISM
- ▶ Healthy graft
- ▶ Low risk of rejection
- ▶ Reasonable patient
- ▶ **CONCERNS**
  - ▶ Astigmatism may change with time (keratoconus)
  - ▶ Astigmatism will change if graft is repeated
  - ▶ Possibly benefits to femto AK – can be removed if cornea is removed

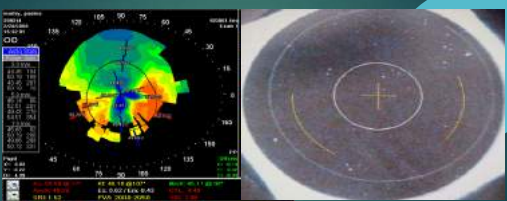


### Which is better?

#### Toric IOL or Femto AK in PK?



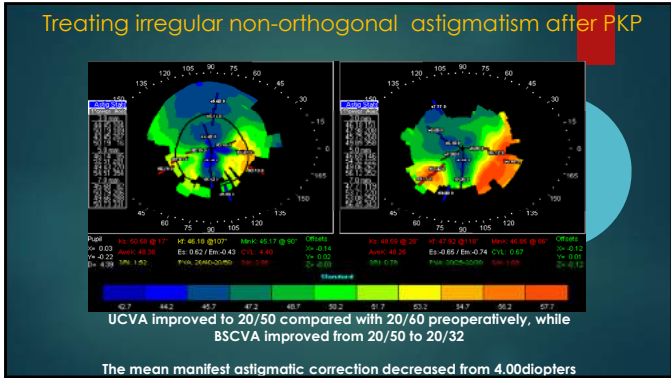
### Treating irregular non-orthogonal astigmatism after PKP



Courtesy of Sonia Yoo, MD

**Femtosecond-assisted astigmatic keratotomy for post-keratoplasty irregular astigmatism**

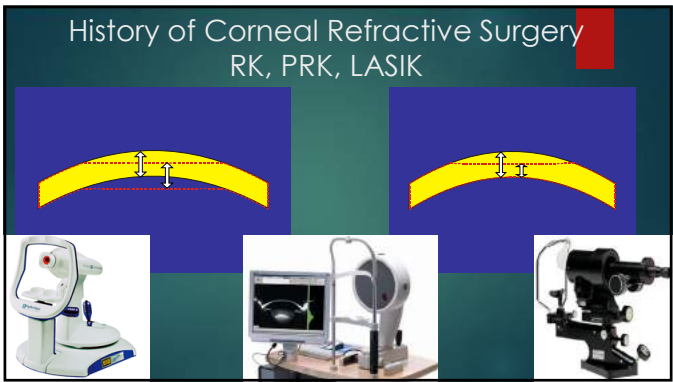
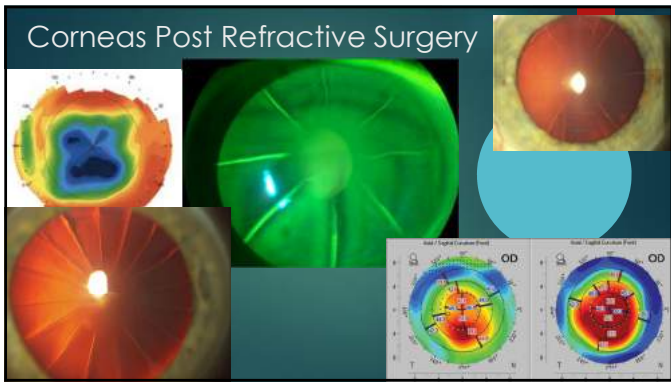
Courtesy: Dr. Wiponwong, M.D. (PKP) Courtesy: Dr. Yoo, M.D. (Astigmatic AK) M.D. (PKP) ©2008 by California, USA



### History of Corneal Refractive Surgery

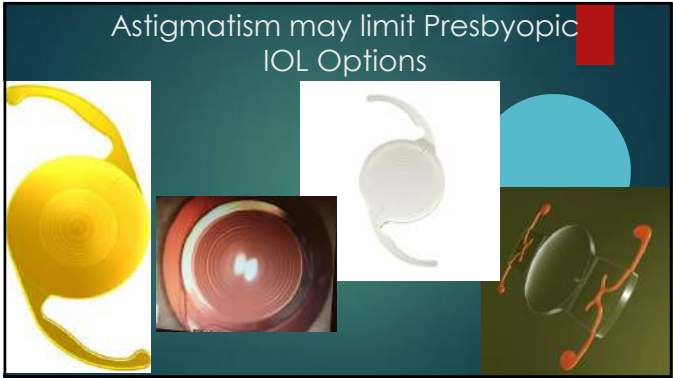RK, PRK, LASIK

Post-op Surprises!  
Limitations in IOL options



### What makes a good toric candidate after prior corneal refractive surgery?

- ▶ Primarily regular stable repeatable astigmatism
- ▶ Minimal OSD
- ▶ Old records
- ▶ Reasonable expectations
- ▶ No signs of progression or corneal steepening over time
- ▶ No signs of unstable vision throughout the day - RK



### Power and Alignment are Critical!

### Other treatment options...

- ▶ Scleral Contact Lenses
- ▶ I-design
  - ▶ Topo-guided LASIK with or without cross-linking
- ▶ IC8 – Pinhole IOL

### Indications for Scleral Contact Lenses

- ▶ **Ocular Surface Disease**
  - ▶ Dry eye/K sicca
  - ▶ Sjogren's
  - ▶ Rheumatoid
  - ▶ Post-radiation
  - ▶ GVHD
  - ▶ Limbal stem cell deficiency
  - ▶ Epidermal Ocular Disorders
  - ▶ Neurotrophic keratitis
  - ▶ Exposure keratopathy
- ▶ **Corneal Epitheliopathy/Inflammation**
  - ▶ Corneal Degenerations
    - ▶ Keratoconus
    - ▶ Pellucid
    - ▶ Terrien's
    - ▶ Salzmann's
  - ▶ Corneal Dystrophy
    - ▶ Granular
    - ▶ Lattice
  - ▶ Post-operative Astigmatism
    - ▶ RK/PK/LASIK/PRK
  - ▶ Corneal Scarring
    - ▶ Trauma/Infection

### HZO Corneal Scarring

### I-Design – more precise treatment for irregular corneas

### IC-8 Small Aperture IC

Pinhole IOLs

## Pearls for Astigmatism Correction in Complex Cases

1. Advise patients of inaccuracies/limitations
2. Limitations of Technology
3. **\*\*\*RULE of ERROR:**
  - Use lowest K = Highest IOL power\*\*\*
  - Err on side of myopia
4. Multiple measurements – look for consistency
5. Beware of OSD – pretreat
  - Effects on power and axis
6. Beware of premium IOLs!
  - Expectations associated with cost!
7. Newer technologies may provide better solutions

*Thank you*

**Superficie Ocular /Córnea**  
**Ocular Surface/Cornea**

**Adelgazamiento Atípico:**

**¡Ayuda Por Favor!**  
**Atypical Thinning: Help Please!**



**Dr. Jaime Martinez Martinez**

www.bascompalmer.org

# Atypical Thinning: Help Please!

Jaime D. Martinez, MD  
Assistant Professor  
Bascom Palmer Eye Institute

Bascom Palmer Eye Institute Health MILLER

www.bascompalmer.org

27 y/o male pts referred due to blurry vision and corneal neovascularization

OD BCVA : 20/25 OS BCVA : 20/70

Bascom Palmer Eye Institute Health MILLER

www.bascompalmer.org

## Differential diagnosis

- 1-Infectious
- 2-Inflammatory
- 3- Mechanical

Bascom Palmer Eye Institute Health MILLER

www.bascompalmer.org

## Peripheral Thinning +/- ulcer

- Pellucid Marginal Degeneration
- Terrien's Marginal Degeneration
- Dellen
- Mooren's Ulcer
- Peripheral Ulcerative Keratitis

Bascom Palmer Eye Institute Health MILLER

www.bascompalmer.org

## PUK/Scleritis Associated

Disease	Systemic Findings	Diagnosis	%
Rheumatoid Arthritis	symmetrical arthritis, ulnar deviation, skin nodules	RF, ANA, CCP	17-33%
Wegener's Granulomatosis	Epistaxis, sinusitis, hemoptysis, hematuria, arthralgia, constitutional symptoms, saddle nose	ANCA, UA, biopsy	4-8%
Relapsing Polychondritis	Pain/swelling of ear pinnae, tracheal inflammation, collapsed nasal bridge, hearing loss, polyarthrits	ESR, biopsy	2-6%
Inflammatory Bowel Disease	Diarrhea, bloody stools, anemia, fistulas, weight loss	Colonoscopy and Biopsy	2-4%
Systemic Lupus Erythematosus	Malar rash, skin photosensitivity, arthritis, pleuritis, pericarditis, seizures	ANA, DS-DNA	1-4%
Spondyloarthropathies	Arthritis, low back stiffness (AS), urethritis and conjunctivitis (Reiter's syndrome), skin lesions (psoriatic arthritis)	HLA-B27	1-3%
Polyarteritis Nodosa	Constitutional symptoms, arthralgia, purpura/ neuropathy, hypertension, nephropathy	ANCA, UA, biopsy	0.5-1%

Okravci et al, 2005 and Smith et al, 2007


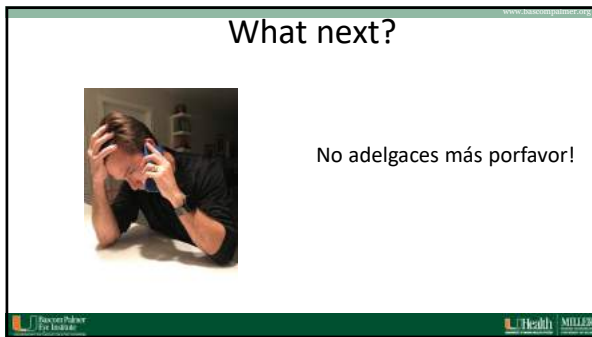
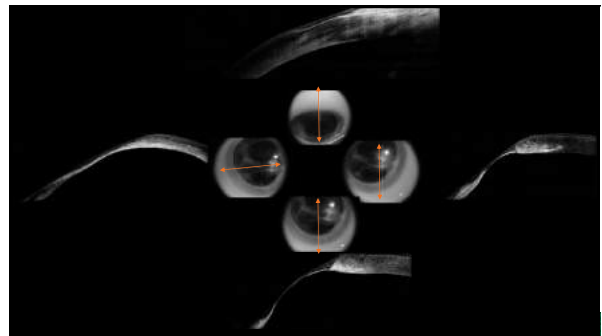
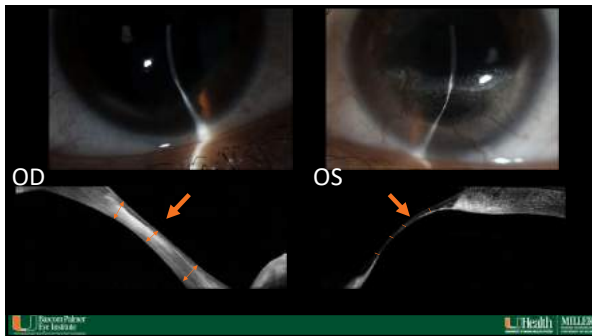
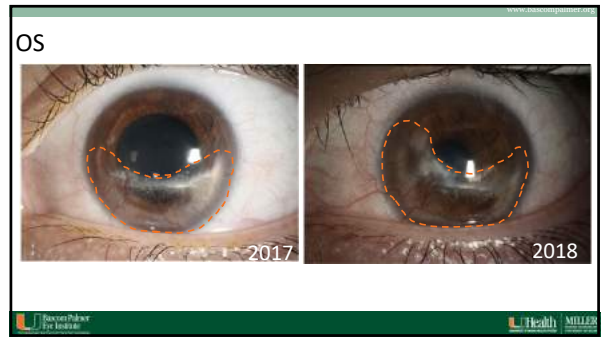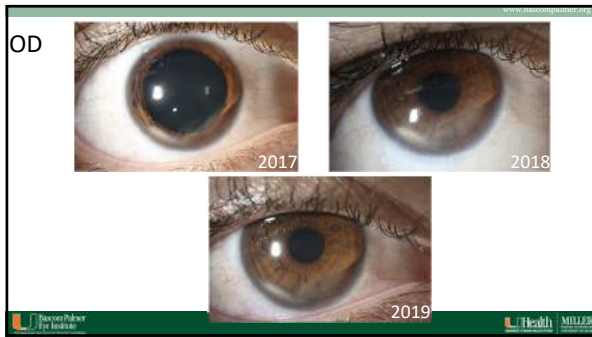
Bascom Palmer Eye Institute Health MILLER

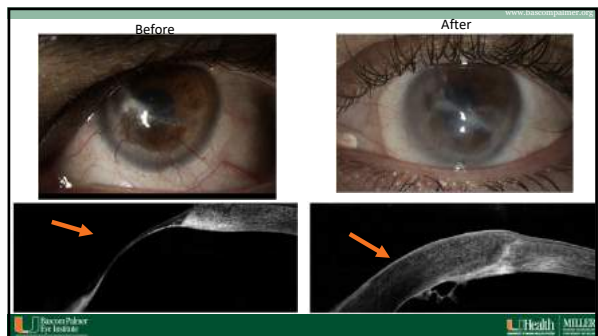
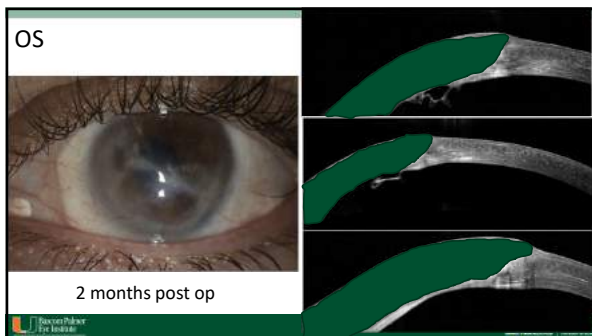
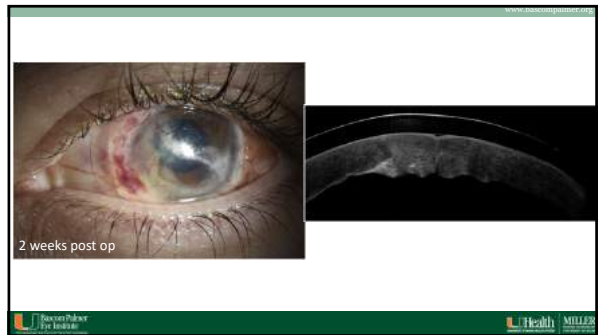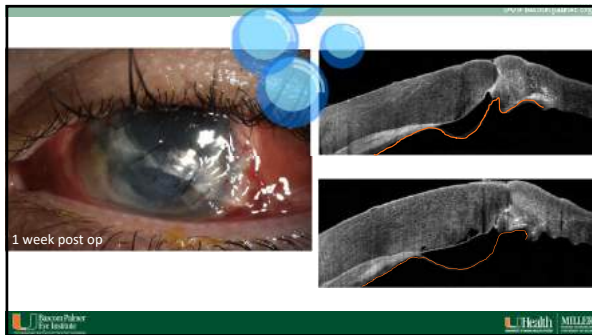
www.bascompalmer.org

## Next step?

Test	Result
CBC and complete metabolic panel	Negative
ESR CRP	Negative
RF	Negative
ANA	Negative
TB quantiferon	Negative
RPR	Negative
ANCA	Negative
HLA B27 Negative	Negative


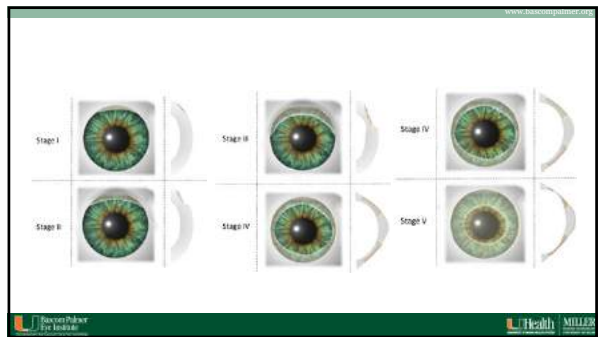
Bascom Palmer Eye Institute Health MILLER

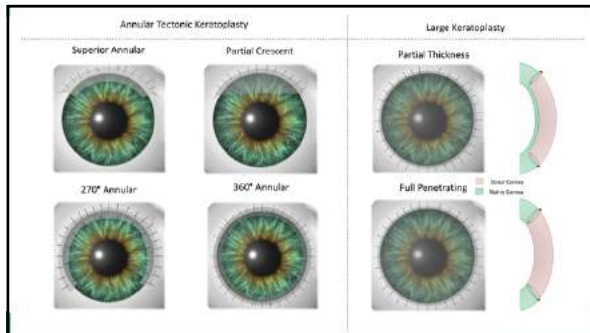




### Terrien's Marginal Degeneration

- ✓ 20-40 years old
- ✓ Male > Female
- ✓ Non-inflammatory,
- ✓ Unilateral or asymmetrically bilateral peripheral corneal thinning



### Corneal Collagen Cross-linking for Terrien Marginal Degeneration

Forhad Helou, MD, PhD; Zisis Gatzouras, MD, PhD; Theo G. Seiler, MD; Theo Seiler, MD, PhD

**ABSTRACT**

**PURPOSE:** To report the long-term clinical outcome of a patient diagnosed as having Terrien marginal degeneration (TMD), who was subjected to corneal collagen cross-linking (CXL) with Ultraviolet-A and riboflavin in both eyes.

**METHODS:** Topographical changes were assessed by high-resolution Scheimpflug imaging and anterior segment optical coherence tomography. Ecentric to the thinnest CXL was performed in both eyes while protecting the corneal endothelium. Irradiation was performed with a fluence of 5.4 J/cm<sup>2</sup>, using 3 mW/cm<sup>2</sup> for 30 minutes.

**RESULTS:** Five years of retrospective follow-up showed regression of the keratometric values, a local thickening of the corneal stroma, and bilateral improvement of corrected distance visual acuity.

**CONCLUSIONS:** CXL may arrest progression in TMD and even reverse the catabolic process in the corneal stroma. CXL might represent an alternative therapeutic approach for the management of TMD.

*J Refract Surg. 2014;30(7):498-500.*

### Take Home Message

1. Peripheral thinning always think of systemic or infection causes.
2. Observation is valid, but beware that cornea can get thinner.
3. Despite surgery, victory cannot be taken.
4. Preventive care for patients, such as not rubbing the eyes, and eye protection
5. Monitor patient frequently <250 um corneal thickness

Ocular Surface Team

1st gen 5th gen My dad 2nd gen 4th gen 3rd gen

# Gracias

## Atypical Thinning: Help Please!

Jaime D. Martinez, MD  
Assistant Professor  
Bascom Palmer Eye Institute

# **Superficie Ocular /Córnea** **Ocular Surface/Cornea**

**Edema Post Facio: ¿Ahora qué Hago?**  
**Edema Post Phaco: Now What?**



**Dr. Victoria Chang**

www.aao.com/paper.org

# Edema post- phaco: Now what?

Victoria S. Chang, MD

XLIII Inter-American Course in Clinical Ophthalmology  
VIRTUAL EDITION


Rayson Palmer Eye Institute Health MILLER

www.aao.com/paper.org

## Patient 1

69yo M with FECD presents with blurred vision  
1mo s/p CEIOL OD

$V_{a_{sc}} < \begin{matrix} HM \rightarrow NI \\ 20/30 \end{matrix}$



Rayson Palmer Eye Institute Health MILLER


www.aao.com/paper.org

## Patient 1

69yo M with FECD presents with blurred vision  
1mo s/p CEIOL OD

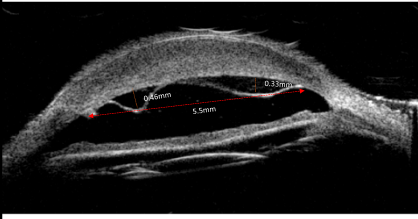
$V_{a_{sc}} < \begin{matrix} HM \rightarrow NI \\ 20/30 \end{matrix}$

Pachy - unable





Rayson Palmer Eye Institute Health MILLER

www.aao.com/paper.org



Rayson Palmer Eye Institute Health MILLER

www.aao.com/paper.org

Rayson Palmer Eye Institute Health MILLER

www.aao.com/paper.org

## Patient 2

- 79 yo M undergoes uneventful CEIOL OD
- Peripheral temp DMD noted at the CCI intraop
- Air bubble was injected at the end of the case
- Usual post- op drops + Muro 128 gtt

Rayson Palmer Eye Institute Health MILLER

www.aseacomputer.org

## Patient 2

POW#1

$Va_{sc} = 20/40$

<1mm <1mm

Rayson Palmer Eye Institute Health MILLER

www.aseacomputer.org

## Descemet Membrane Detachment (DMD)

- Extracapsular cataract extractions (2.5%)
- Phacoemulsification (0.5%)
- Most are small & resolve spontaneously (40%)

Rayson Palmer Eye Institute Health MILLER

www.aseacomputer.org

## Risk Factors

INTRINSIC FACTORS	SURGICAL FACTORS
<ul style="list-style-type: none"> <li>• FECD</li> <li>• PXF</li> <li>• Corneal ectatic disorders</li> <li>• Shallow chamber</li> <li>• Age &gt; 65</li> <li>• Nuclear grade <math>\geq 4</math></li> </ul>	<ul style="list-style-type: none"> <li>• Anterior &amp; shelved incisions CCI</li> <li>• Narrow &amp; tight incisions</li> <li>• Soft eye</li> <li>• Dull blades</li> <li>• Engaging DM during IOL implantation or I&amp;A</li> <li>• Injection of OVD between DM &amp; stroma</li> <li>• Prolonged US time &gt; 60s</li> </ul>

Rayson Palmer Eye Institute Health MILLER

www.aseacomputer.org

## Classification & Treatment Algorithms

**CONTROVERSY**

Rayson Palmer Eye Institute Health MILLER

www.aseacomputer.org

## Mackool 1977

PLANAR  $\leq 1mm$  😊

NONPLANAR  $> 1mm$  ☹️

Rayson Palmer Eye Institute Health MILLER

www.aseacomputer.org

## Assia 1995

DD without scrolling can reattach spontaneously even if  $> 1mm$

Rayson Palmer Eye Institute Health MILLER

### Jain 2013

Mild			Observation
Moderate			
Severe			

Figure 1. Grading of the severity of Descemet's membrane detachment. 88% achieved <math>C2</math> or less and no peripheral. Median survival 27% at 100 cases and no peripheral. Seven percent 100% at the corner or around corner.

Jain R, Murthy S, Basu S, Ali MH, Sangwan VS. Anatomic and visual outcomes of descemetomy in post-cataract surgery descemet's membrane detachment. *Ophthalmology*. 2013;120(7):1366-1372.

### Jacob 2015

1. Rhegmatogenous DMD
2. Tractional DMD
3. Bullous DMD
4. Complex DMD

Jacob S, Agarwal A, Chaudhry P, Narasimhan S, Chaudhry VN. A new clinico-tomographic classification and management algorithm for Descemet's membrane detachment. *Cont Lens Anterior Eye*. 2015;36(5):327-333.

### Jacob 2015

```

    graph TD
      DMD[DMD] --> Rhegmatogenous
      DMD --> Tractional
      DMD --> Bullous
      DMD --> Complex
      Rhegmatogenous --> Planar_Peripheral[Planar & Peripheral 3mm]
      Planar_Peripheral --> large1[large]
      large1 --> Desce_EK1[Descemetomy or EK]
      Planar_Peripheral --> Observation
      Tractional --> large2[large]
      large2 --> Desce_Tom[Descemetotomy]
      Bullous --> large3[large]
      Bullous --> Small_peripheral[Small or peripheral]
      Small_peripheral --> Observation
      Complex --> large4[large]
      large4 --> Desce_EK2[Descemetomy or EK]
  
```

Jacob S, Agarwal A, Chaudhry P, Narasimhan S, Chaudhry VN. A new clinico-tomographic classification and management algorithm for Descemet's membrane detachment. *Cont Lens Anterior Eye*. 2015;36(5):327-333.

### HELP algorithm 2015

Height  
Extent  
Length

```

    graph TD
      DMD[Descemet membrane detachment] --> H[Height <math><math>100</math></math>]
      DMD --> E[Extent <math><math>100</math></math>]
      DMD --> L[Length <math><math>100</math></math>]
      H --> H1[Height <math><math>100</math></math>]
      H --> H2[Height <math><math>100</math></math>]
      H --> H3[Height <math><math>100</math></math>]
      E --> E1[Extent <math><math>100</math></math>]
      E --> E2[Extent <math><math>100</math></math>]
      E --> E3[Extent <math><math>100</math></math>]
      L --> L1[Length <math><math>100</math></math>]
      L --> L2[Length <math><math>100</math></math>]
      L --> L3[Length <math><math>100</math></math>]
      H1 --> Zone1[Zone 1]
      H2 --> Zone2[Zone 2]
      H3 --> Zone3[Zone 3]
      E1 --> Zone1
      E2 --> Zone2
      E3 --> Zone3
      L1 --> Zone1
      L2 --> Zone2
      L3 --> Zone3
      Zone1 --> YAG[YAG laser]
      Zone2 --> YAG
      Zone3 --> YAG
      Zone1 --> Desce_Tom[Descemetotomy]
      Zone2 --> Desce_Tom
      Zone3 --> Desce_Tom
      Zone1 --> Desce_EK[Descemetomy or EK]
      Zone2 --> Desce_EK
      Zone3 --> Desce_EK
  
```

Figure 2. The HELP protocol (Z1 = zone 1; Z2 = zone 2; Z3 = zone 3).

Kumar DA, Agarwal A, Sivaganam S, Chandrasekar R. Height-, extent-, length-, and pupil-based (HELP) algorithm to manage post-phacoemulsification Descemet membrane detachment. *J Cataract Refract Surg*. 2015;41(1):164-169.

### Surgical Management

- Air injection
- Gas injection (14% C<sub>3</sub>F<sub>8</sub> & 20% SF<sub>6</sub>)
- OVD

Failure rate 30%

```

    graph TD
      Title[Management of types of DMDs] --> S1[Superior half with planar edges]
      Title --> S2[Superior half with scalloped edges]
      Title --> I1[Inferior half with planar edges]
      Title --> I2[Inferior half with scalloped edges]
      Title --> E[Extensively involving entire cornea]
      S1 --> I1a[Intracameral CDFB]
      S2 --> I2a[Intracameral CDFB]
      I1 --> I1b[Intracameral CDFB]
      I2 --> I2b[Intracameral CDFB]
      E --> I3a[Intracameral CDFB]
  
```

Sharma N, Gupta S, Mahapatra P, Sharmapuri P, Nagpal R, Vajpayee RB. Anterior Segment Optical Coherence Tomography-Guided Management Algorithm for Descemet Membrane Detachment After Intraocular Surgery. *Cornea*. 2015;34(9):1170-1174.

### Surgical Management cont.

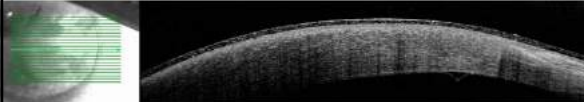
- Suturing of the membrane to the stroma
- Nd:YAG laser for bullous DMD
- DSO
- Corneal transplant

Das M, Begum Shaik M, Nidhikrishnan N, Purna VN. Descemet Membrane Suturing for Large Descemet Membrane Detachment After Cataract Surgery. *Cornea*. 2020;39(1):52-55.

www.aaocomputer.org

### Patient 1 POW1

- Descemetopexy performed with 20% SF<sub>6</sub>
- DM attached
- VA only CF




Rayson Palmer Eye Institute Health MILLER

www.aaocomputer.org

### Patient 2

- We ultimately placed a 2<sup>nd</sup> air bubble at POM1 since vision was still not improved
- 1 wk later, patient was 20/20



Rayson Palmer Eye Institute Health MILLER

www.aaocomputer.org

### Thank you!



Rayson Palmer Eye Institute Health MILLER


**Superficie Ocular /Córnea**  
**Ocular Surface/Cornea**

**Cuando la Ceguera “Corneal” Continúa**  
**When “Corneal” Blindness Continues**



**Dr. Allister G. Gibbons**

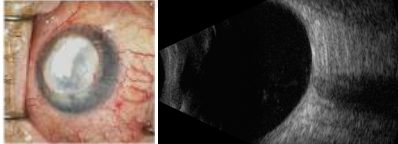
KPRO Went well.  
Why can't this patient see better?



Allister Gibbons MD  
Curso Virtual - Nov 2020


**Case**

JAN 2019 - 68yo Female – LP IN OS // IOP 15 mmHg  
– Previously healthy CL user had fungal keratitis OS  
– Tectonic/therapeutic PKP Oct 2018



Curso Virtual - Nov 2020

- FEB 2019 - Optical PKP (2<sup>nd</sup> graft)
  - Cataract extraction + IOL
  - Normal IOP
  - Persistent KED:
    - Dx Neurotrophic Keratopathy
    - AMG/BCL/AST
    - 20/400



Curso Virtual - Nov 2020


**REPEAT PKP & CE+IOL**

- Returns DEC 2019 – Failed (2<sup>nd</sup> graft)
- Patient needs binocularity for professional purposes
  - Already 2 failed grafts, high risk
  - Risks and benefits - **Observe Vs Kpro Vs PKP (+IM)**
    - Not my typical recommendation for Kpro

Sumayya Ahmad, et al. Boston Type 1 Keratoprosthesis versus Repeat Donor Keratoplasty for Corneal Graft Failure: A Systematic Review and Meta-analysis. Ophthalmology 2016 - Jan;123(1):165-77.


Curso Virtual - Nov 2020

- Feb 2020 – Kpro + PPV
  - GDI and all – Baerveldt 350
  - Uneventful – Mild vit heme
  - Mild early hypotony
- March 2020 - COVID
  - Best vision 20/100
  - High IOPs early high 20's – Left for Michigan

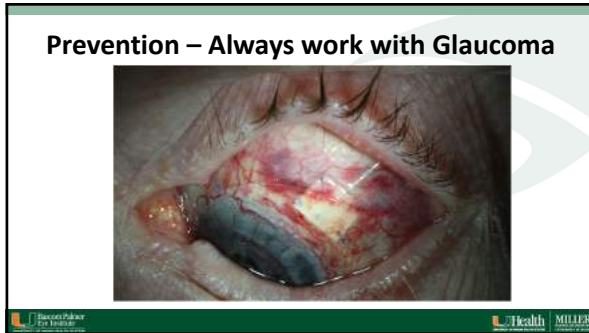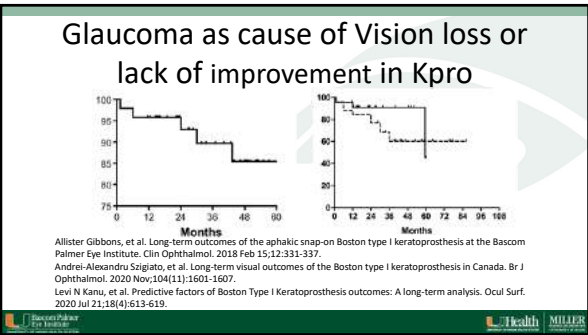
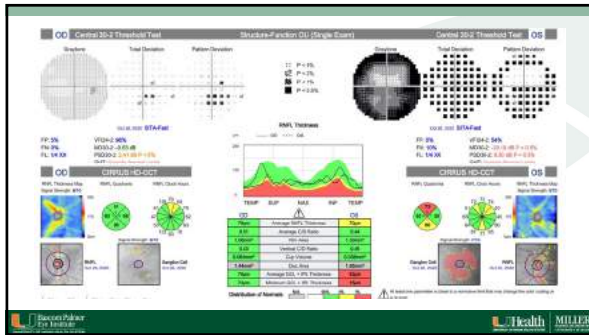


Curso Virtual - Nov 2020

- In Michigan
  - Vision not improving
  - VH clearing
- Returns to Florida  
October 2020
  - Vision is 20/70
  - Normal IOP



Curso Virtual - Nov 2020



### How can we detect diseased eyes?

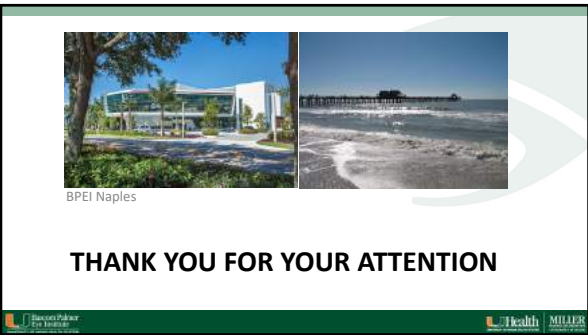
Use of Intraocular Videoendoscopic Examination in the Preoperative Evaluation of Keratoprosthesis Surgery to Assess Visual Potential

EMILIO C. FARIAS, HIRAI E. GOTTLIEB, THOMAS A. ALBINI, ALESSANDRO DEBEOCAL, GUILHERMO AMBRÓSIA, CAROLINA BETAUCCURTI, JEAN-ARNO PAREL, NAVY C. OLIVEIRA, ALLISTER GIBBONS, JOSE M. YARIGAS, AND VICTOR E. PEREZ. Ophthalmol 2014;118:803-806.

B-scan ultrasound, visual electrophysiology and perioperative videoendoscopy for predicting functional results in keratoprosthesis candidates

Luzia Diegues Silva,<sup>1,2</sup> Albert Santos,<sup>1</sup> Flavio Hirai,<sup>1</sup> Norma Allemann,<sup>1,2</sup> Adriana Berezovsky,<sup>1</sup> Solange Rios Salomão,<sup>1</sup> Paulo Ricardo Chaves de Oliveira,<sup>1</sup> Gabriel Andrade,<sup>1</sup> André Mala,<sup>1</sup> Luciene Barbosa de Sousa,<sup>1</sup> Lauro Augusto de Oliveira.<sup>1</sup> Silva LS, et al. Br J Ophthalmol 2020;94:1-5. doi:10.1136/bjophthalmol-2020-316967

- ### Discussion
- Was the damage there prior?
    - The fact vision has been stable speaks of stability
  - Could that level of damage be expected even before 6 months?
  - Roles of other type of Neuropathy in these Kpro patients?
    - Or just a reflection of a complex eye.



**Superficie Ocular /Córnea**  
Ocular Surface/Cornea

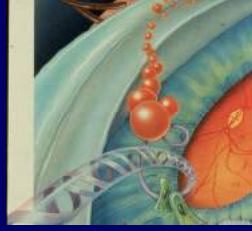**Rotación de Doctores en**  
**Conjuntivitis Crónica**

Chronic Conjunctivitis and  
Revolving Eye Doctors



**Dr. Terrence P. O'Brien**

## Curso Interamericano 2020



## Terrence P. O'Brien, MD

Professor of Ophthalmology  
Ocular Microbiology Laboratory  
Bascom Palmer Eye Institute  
University of Miami  
Miller School of Medicine  
Palm Beach, Florida USA

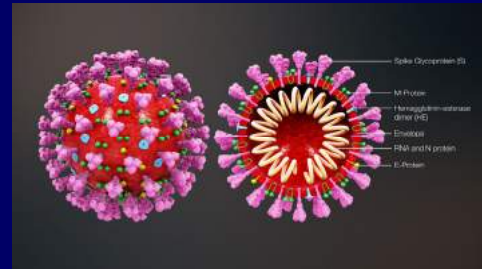


## Faculty Disclosures

•None

20 20

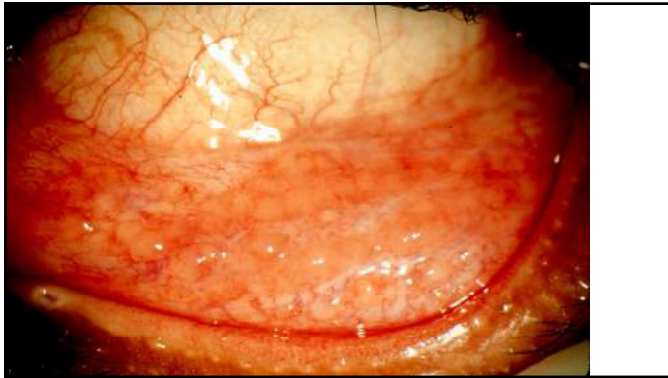## The Year of Ophthalmology



## Challenging Case

- 71 year old African American lady with 5 month history of ocular irritation, redness, burning, photosensitivity and occasional tearing with discharge in her left eye >> right eye





## Challenging Case

- Has seen 4 “specialists” and tried many treatments with multiple eyedrop medications without amelioration of her symptoms

### Doctor #1

- Dx: *Allergic Conjunctivitis*
- Rx: 1) Loteprednol 0.38% (Lotemax SM) one drop both eyes 3x/day x 1 week, 2x/day x 1 week, 1x/day x 1 week, then STOP
- 2) Bepotastine besilate 1.5% (Bepreve) one drop to both eyes 2x/day
- 3) Preservative-free artificial tears 4x/day

•\$\$ 250.00

### Doctor #2

- Dx: *Keratoconjunctivitis sicca*
- Rx: 1) Loteprednol 0.38% (Lotemax SM) one drop both eyes 3x/day x 1 week, 2x/day x 1 week, 1x/day x 1 week, then STOP
- 2) Lifitegrast 5% (Xiidra) one drop to both eyes 2x/day
- 3) Preservative-free artificial tears 4-6x/day
- 4) Punctal plugs (0.7 mm), lowers

•\$\$\$ 550.00

### Doctor #3

- Dx: *Ocular Rosacea/Meibomian gland dysfunction*
- Rx: 1) Loteprednol 0.38% (Lotemax SM) one drop both eyes 3x/day x 1 week, 2x/day x 1 week, 1x/day x 1 week, then STOP
- 2) Doxycycline 50 mg by mouth 2x/day x 2 weeks
- 3) Preservative-free artificial tears 4x/day
- 4) Pulsatile thermal massage (*LipiFlow*)

•\$\$\$\$ 1050.00

### Doctor #4

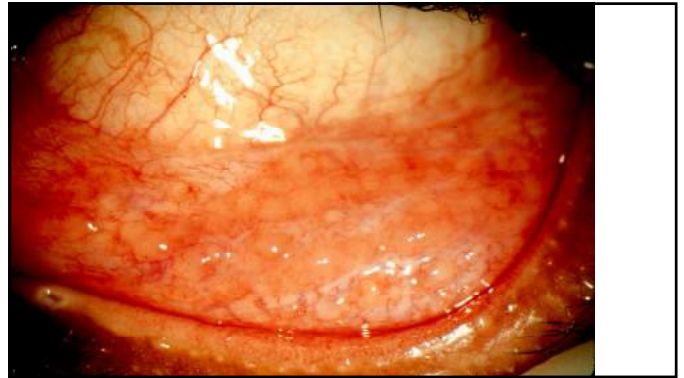
- Dx: *Chlamydial keratoconjunctivitis*
- Rx: 1) Conjunctival Culture
- 2) Doxycycline 100 mg by mouth 2x/day x 2 weeks
- 3) Preservative-free artificial tears 4x/day
- 4) Referral to Sexually Transmitted Disease Clinic

•\$ 50.00

- Culture Negative; *Policeman son requests after hours meeting with Doctor #4*

## Challenging Case

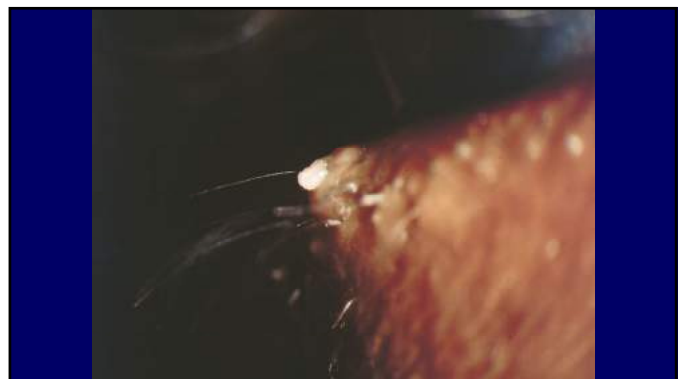
- 71 year old African American lady with 5 month history of ocular irritation, redness, burning, photosensitivity and occasional tearing with discharge in her left eye >> right eye
- Medical History: Breast CA status post chemotherapy
- Ocular medications: None
- Social History: Widowed. Sexually inactive.

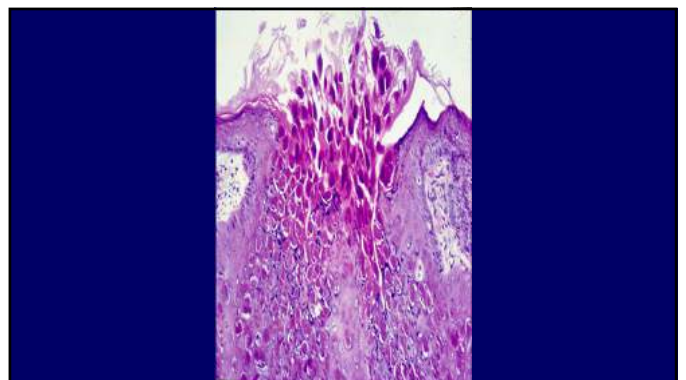
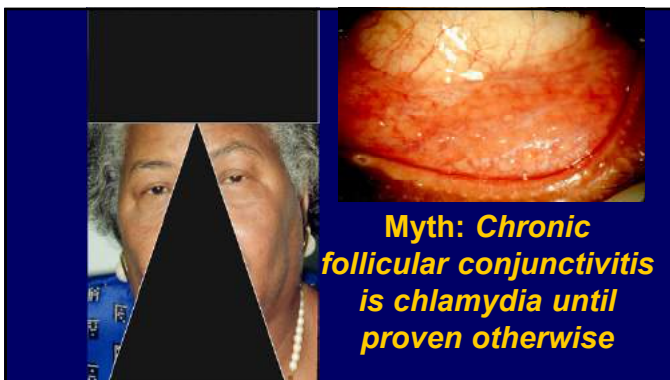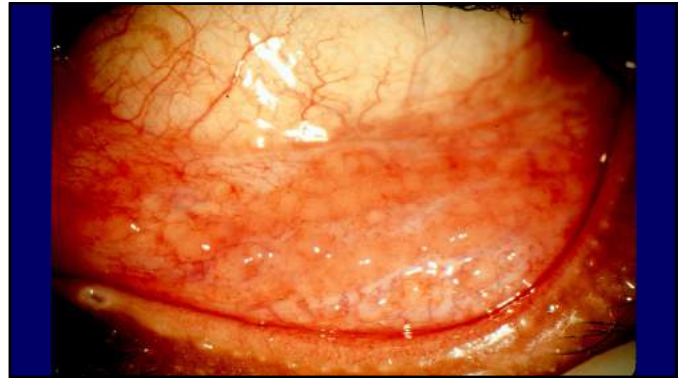

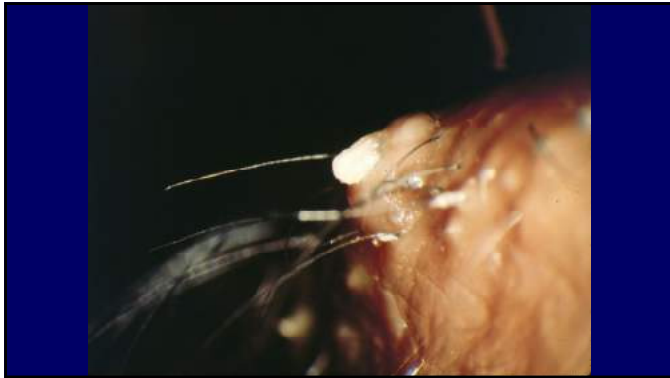
## What is Your Diagnosis, Doctor?

- 1) *Epstein-Barr Virus Conjunctivitis*
- 2) *Conjunctival B-cell lymphoma*
- 3) *Toxic Keratoconjunctivitis*
- 4) *Chronic Adenoviral Conjunctivitis*
- 5) *Other?*

See the Forest  
Through the  
Trees...





**Dx: *Molluscum contagiosum***

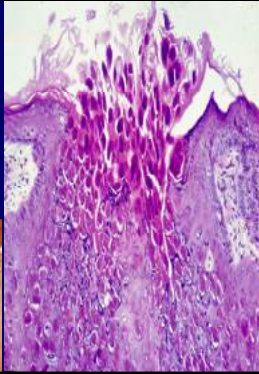
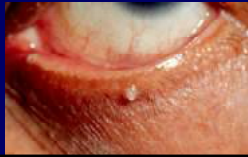- Caused by a DNA Pox virus-*MC virus*
- Umbilicated eyelid lesion with central core
- Viral proteins shed from lid lesions into the tear film trigger hypersensitivity reaction and *chronic unilateral follicular conjunctivitis*, punctate keratopathy, subepithelial opacities, pannus
- May resolve spontaneously
- Treatment may hasten resolution

**Rx: *Molluscum contagiosum***

- Excision
- Incision and Curettage
- Cryotherapy
- Cauterization
- Topical chemical agents (e.g. *Silver nitrate*)
- Antiviral agents
- Oral cimetidine

**Myth: Chemical  
Cautery preferred  
for Molluscum**

Unroofing with  
removal of central  
keratin core (25G needle)



**See the Forest Through the Trees**



**Muchas Gracias**



# **Superficie Ocular /Córnea**

## **Ocular Surface/Cornea**

**Queratinización Severa de la Superficie Ocular en  
Pacientes Pediátricos: Una Idea para Digerir**

**Severe Ocular Surface Keratinization in Pediatric  
Patients: A Thought to Digest**



**Dr. Victor L. Perez**

**Duke Eye Center**  
Foster Center For Ocular Immunology

Severe Ocular Surface Keratinization in Pediatric Patients:  
A Thought to Digest

XLII Inter-American Course in Clinical Ophthalmology - VIRTUAL  
EDITION

Hazem Mousa, MD  
Matias Soifer, MD  
Victor L. Perez, MD  
Foster Center for Ocular Immunology  
Duke Eye Center

**Duke Eye Center**  
Foster Center For Ocular Immunology

Case Presentation

**Presentation**

- 9 year old boy accompanied by his mother
- Presenting for **bilateral eye pain** and redness (four weeks ago)
- Referred after failure of topical steroid therapy
- Patient known to be **autistic** from a young age
- Ocular history was unremarkable

**Ocular Examination**

- Visual Acuity was **Counting Fingers** in both eyes
- Pupils were both reactive to light
- Ocular examination was limited due to lack of cooperation

**Examination Under Anesthesia**

Examination under Anesthesia was then required and showed:

- **Cornea:** Xerosis, haze, punctate epitheliopathy with an inferior **3x3 mm** sterile epithelial defect bilaterally
- **Conjunctiva:** Homogenous keratinization bilaterally



**Past Medical History**

- Diet consisted of only **fried potatoes** for more than 2 years
- Alternatives for nourishment have failed in the past
- Patient was in the **5<sup>th</sup>** percentile for height for his age



**Investigations**

Exam Under Anesthesia  
Labs including nutritional panel were taken and revealed:

- Vitamin A level of **<5.1** mcg/dL (reference 50-200 mcg/dL)
- Vitamin D and Vitamin B12 also found to be below normal
- Remainder of blood workup was insignificant

*A diagnosis of Vitamin A deficiency was made*

## Management

**Ocular Management:**

- Bilateral Kontur lenses were placed
- Topical Moxifloxacin four times daily
- Artificial tears and ointment lubrication

**General Management:**

- Admitted to the hospital for Vitamin A supplementation

Duke Eye Center  
Duke University Medical Center


## Case Significance

- Diet selectivity due to a psychiatric illness caused the ocular findings
- Nutritional deficiencies are rarely seen or suspected in the US
- Ophthalmologists often under-suspect systemic disease
- Such can lead to underdiagnoses of this disease

Duke Eye Center  
Duke University Medical Center

## Autism and Malnutrition

- Autistic children often report a restricted/selective diet
- Interest in select textures with aversion to others
- This selectivity anecdotally includes “yellow” foods
- This places these individuals at increased risk of malnourishment




Duke Eye Center  
Duke University Medical Center

## Outcome


One month later:

- Ocular symptoms were no longer present
- Visual acuity was **20/40** right eye and **20/50** left eye
- Near complete resolution of the ocular surface findings




Duke Eye Center  
Duke University Medical Center

## Outcome



Duke Eye Center  
Duke University Medical Center

## Outcome



Duke Eye Center  
Duke University Medical Center

## Conclusion

- Vitamin A is essential for normal ocular and systemic functioning
- Disease is common worldwide but rare in developed countries
- Nutritional deficiencies and specific diets are common in Autism
- Xerophthalmia indicates a severe underlying Vitamin A deficiency
- Delay in diagnosis can lead to irreversible blindness and death



# **Oftalmología Pediátrica**

## **Pediatric Ophthalmology**

### **Caso 2**

### **Case 2**





**Dr. Craig A. McKeown**

Oh No!  
My new patient has had 3 prior  
strabismus procedures.  
What do I do?

Craig A. McKeown, MD  
Bascom Palmer Eye Institute

cmckeown@med.miami.edu




The speaker has no financial conflicts





Case

- 55 yr old female with acquired esotropia from 6<sup>th</sup> nerve palsy
- Prior surgery x3 in another country
- There are no old records!

What do we do?






What do we do?






What are we concerned about?



1. Characteristics of the strabismus
2. If surgery is to be considered, what muscles are available?
3. What is the optimal procedure?
4. What is the risk of inducing anterior segment ischemia (ASI)?



Signs Post Op Day #1




Sequelae  
(different patient)



### To Help Determine the Risk of ASI, the Evaluation Should Include

1. Examination of the surface of both eyes to try to determine which of the muscles received prior surgery
2. Look for:
  - a) Surgical scars
  - b) Anterior ciliary vessels at the original insertion site



bascompalmer.org

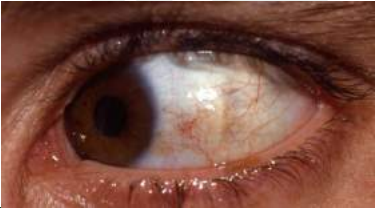
- Anterior ciliary vessels (ACV) can help determine which rectus muscles received prior surgery
- A drop of topical phenylephrine may help identify ACV


bascompalmer.org

### Eye with prior muscle surgery

1. Visible stump of original tendon insertion
2. Absence of anterior ciliary vessels




(different patient)




bascompalmer.org

### Lateral aspect of globe

1. Choroid visible behind original insertion
2. Absence of anterior ciliary vessels





(different patient)



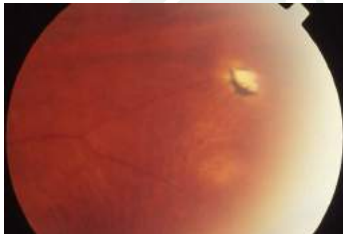

bascompalmer.org

### Other Clues

bascompalmer.org

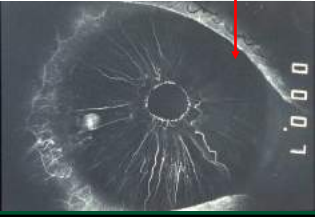
### Dilated examination shows chorioretinal scar after prior surgery

bascompalmer.org

### Iris Fluorescein Angiography

- May help determine which rectus muscles received prior surgery
- Delayed filling of medial aspect of iris

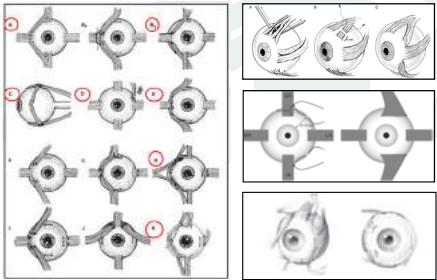


www.cybersight.org

### Surgical Planning

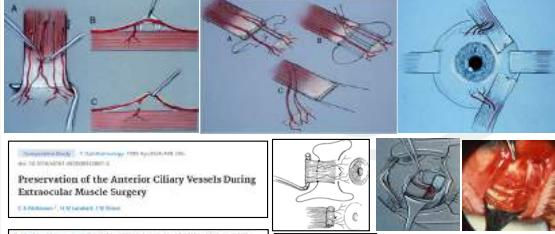
1. Consider risk factors for ASI
2. Age is a very important risk factor
3. At times, the ideal procedure from a mechanical perspective creates a significant risk of ASI
4. There are a number of surgical treatment options in such circumstances

### Several Conventional Transposition Techniques Preserve a portion of the ACV



www.cybersight.org

### ACV Sparing procedures have also been described



Preservation of the Anterior Ciliary Vessels During Extraocular Muscle Surgery  
S. K. H. Hsu, J. A. K. Hsu, J. H. Hsu

Modified Rectus Tuck to Preserve ACV  
Wright KW, Lanier AB. JPOS 1991; 28:77-81

### The End – Good Luck Thank You for Your Attention



# **Oftalmología Pediátrica**

## **Pediatric Ophthalmology**

### **Caso 3**

### **Case 3**



**Dr. Carla J. Osigian**

## Now you see it... Now you don't

Carla J. Osigian, MD

Assistant Professor of Clinical Ophthalmology  
Pediatric Ophthalmology and Strabismus  
Bascom Palmer Eye Institute

## Disclosures

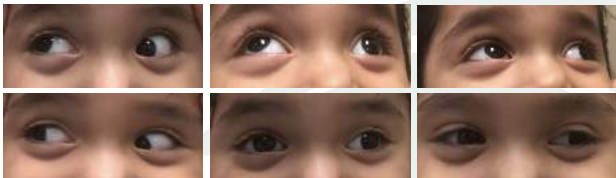
- I have no financial disclosures

## Request

- The patient's parents have given BPEI consent for personal photographs to be used for teaching purposes and presentations.
- However we kindly request that you do not duplicate the images in any way.

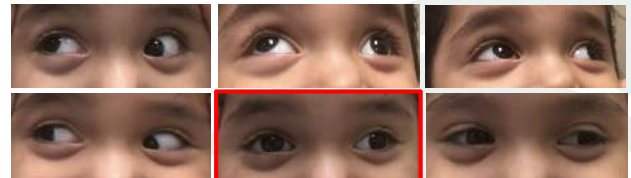## Case

- 2 years old healthy girl
- Left eye out-turn since 7 months old



Diagnoses:

	LXT 40 LHypoT 10	
LXT 35 LHypoT 10	LXT 35 LHypo(T) 4	LXT 35 LHypo(T) 4
	LXT 30	



Diagnoses:

- Left exotropia, constant

	LXT 40 LHypoT 10	
LXT 35 LHypoT 10	LXT 35 LHypo(T) 4	LXT 35 LHypo(T) 4
	LXT 30	

	LXT 40 LHypoT 10	
LXT 35 LHypoT 10	LXT 35 LHypo(T) 4	LXT 35 LHypo(T) 4
	LXT 30	

Diagnoses:

- Left exotropia, constant
- Brown Syndrome, left eye

Bauscom Palmer Eye Institute | University of South Florida | Health | MULLER | 10/20/19

## Brown Syndrome

- Most patients do NOT require surgery
- Surgical treatment when:
  - Marked compensatory head posture
  - Large vertical deviation on primary gaze

Bauscom Palmer Eye Institute | Brown Syndrome management: <http://www.peds-eye.com/ped/5/brownSyndr.htm> | last revised 10/20/19 | Health | MULLER

## Brown Syndrome

- Most patients do NOT require surgery
- Surgical treatment when:
  - Marked compensatory head posture
  - Large vertical deviation on primary gaze

LXT 35 LHypo(T) 4
----------------------

Bauscom Palmer Eye Institute | University of South Florida | Health | MULLER | 10/20/19

## #1: Bilateral LR recession 7.0 mm

POM5

LX(T) 14 LHypo(T) 4
------------------------

- Excellent control
- + stereopsis
- Mild chin up position, no head tilt

Bauscom Palmer Eye Institute | University of South Florida | Health | MULLER | 10/20/19

... 3 months later

- Left head tilt + left face turn

Bauscom Palmer Eye Institute | University of South Florida | Health | MULLER | 10/20/19

... 3 months later



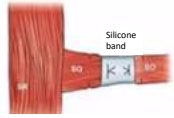
- Left head tilt + left face turn
- Increased HypoT on primary gaze

	LXT 25 LHypoT 15	
LXT 15 LHypoT 14	LXT 15 LHypoT 10	LXT 15 LHypoT 6
	LXT 10	

Bauscom Palmer Eye Institute | University of South Florida | Health | MULLER | 10/20/19

## Management?

TENOTOMY / TENECTOMY	GRADED	
SUTURE SPACER	SUTURE SPACER	SILICONE SPACER
Uncontrolled separation of SO fibers	Low risk of extrusion Allow for intra-operative adjustment <b>Low risk of FB reaction/inflammation</b>	Can extrude Length needs to be cut before-hand Risk of fat adherence and scarring


<https://www.ncbi.nlm.nih.gov/pubmed/23160303>  
 Garg & Abo, Surgical Techniques in Ophthalmology: Strabismus Surgery  
<https://www.jaypedigree.com/book/9789392254485/chapter/1336>

## #2: LSO suture spacer

POW1

LX(T) 10 LHypo(T) 2-4
--------------------------

- Excellent control
- + stereopsis
- No head tilt




<https://www.ncbi.nlm.nih.gov/pubmed/23160303>  
 Garg & Abo, Surgical Techniques in Ophthalmology: Strabismus Surgery  
<https://www.jaypedigree.com/book/9789392254485/chapter/1336>

### ... 2 weeks later

- Recurrent left head tilt + left face turn
- Increased HypoT on primary gaze

LX(T) 20 LHypoT 20	LXT LHypoT 20 LX(T) 20 LHypoT 14	LX(T) 20 LHypoT 6
	LXT 10	




<https://www.ncbi.nlm.nih.gov/pubmed/23160303>  
 Garg & Abo, Surgical Techniques in Ophthalmology: Strabismus Surgery  
<https://www.jaypedigree.com/book/9789392254485/chapter/1336>

### ... 2 weeks later

- Recurrent left head tilt + left face turn
- Increased HypoT on primary gaze
- Marked limitation to elevation on adduction

LX(T) 20 LHypoT 20	LXT 25 LHypoT 10 LX(T) 20 LHypoT 14	LX(T) 20 LHypoT 6
	LXT 10	



<https://www.ncbi.nlm.nih.gov/pubmed/23160303>  
 Garg & Abo, Surgical Techniques in Ophthalmology: Strabismus Surgery  
<https://www.jaypedigree.com/book/9789392254485/chapter/1336>


## What happened? What to do next?

**SUTURE SPACER**

No rigidity to keep the cut tendon ends apart

↓

Suture bridge can act as scaffolding for fibrosis allowing scarring to reunite the cut tendon ends



<https://www.ncbi.nlm.nih.gov/pubmed/23160303>  
 Garg & Abo, Surgical Techniques in Ophthalmology: Strabismus Surgery  
<https://www.jaypedigree.com/book/9789392254485/chapter/1336>

## What to do next?

**SUTURE SPACER**

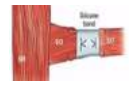
No rigidity to keep the cut tendon ends apart

↓

Suture bridge can act as scaffolding for fibrosis allowing scarring to reunite the cut tendon ends

**SILICONE SPACER**

More rigid material → prevents cut ends from reuniting



<https://www.ncbi.nlm.nih.gov/pubmed/23160303>  
 Garg & Abo, Surgical Techniques in Ophthalmology: Strabismus Surgery  
<https://www.jaypedigree.com/book/9789392254485/chapter/1336>

Explore LSO...

Fibrosis Scarring Muscle Scarring Fibrosis

Bascom Palmer Eye Institute | Health | MULLER

1 hour later...

KEEP CALM AND SNIP SNIP

Bascom Palmer Eye Institute | Health | MULLER

#3: Scar tissue release and LSO tenotomy

POM5

LX(T) 4
No Hypo

- Excellent control
- + stereopsis
- No head tilt

Bascom Palmer Eye Institute | Health | MULLER

To be continued....

LSO palsy

Bascom Palmer Eye Institute | Health | MULLER

Conclusions

- SO graded procedures are more predictable
- Although SO suture spacers are technically easier and have less risk of extrusion/infection/FB reaction, it has the infrequent risk of cut tendon ends reuniting.

Bascom Palmer Eye Institute | Health | MULLER

Thank you!

Bascom Palmer Eye Institute | Health | MULLER

# Oftalmología Pediátrica Pediatric Ophthalmology

## Caso 4 Case 4



**Dr. Hilda Capo**

# Here we Go Again! Strabismus Surgery Reoperations: Consecutive Exotropia

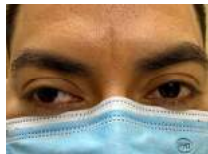

Hilda Capó, M.D.  
John T. Flynn Professor of Ophthalmology Chair  
Bascom Palmer Eye Institute  
University of Miami Miller School of Medicine



• I have no financial interests or relationships to disclose

38 y/o male with history of childhood esotropia treated with patching and strabismus surgery at 20 y/o in Ecuador  
-complains of progressive exotropia OD x 7 years



Exam  
BCVA OD 20/200 OS 20/20-1  
SLE and DFE: unremarkable OU

Strabismus Exam

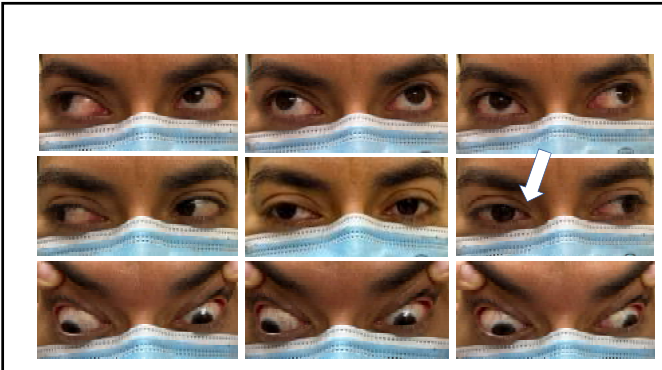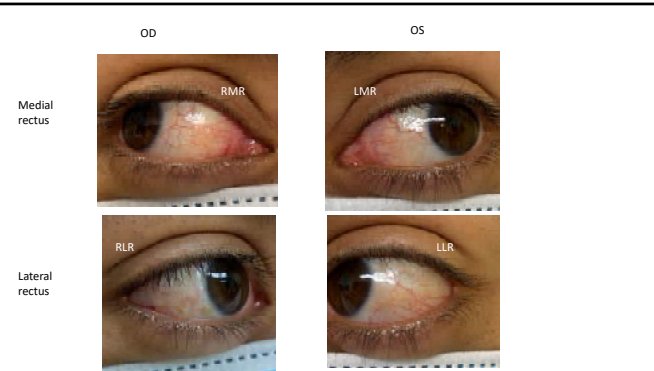
Version	Distance	Near	Head & eye	Teichgraber
Version	20/20-1	20/20-1		
Distance	20/20-1	20/20-1		
Version	20/20-1	20/20-1		
Distance	20/20-1	20/20-1		
Version	20/20-1	20/20-1		
Distance	20/20-1	20/20-1		

Teichgraber: has horizontal right eye only, small angle

Versionalotropia: right exotropia, large angle, constant, constant

DFE present

Chiasm: none



## Underaction previously operated rectus muscle

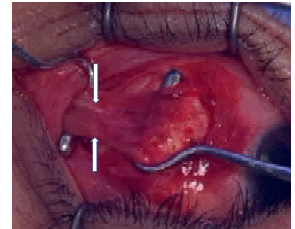
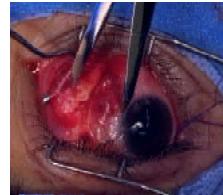
- Excessive prior muscle recession
- Tight antagonist muscle
- Slipped muscle
- Stretched scar

Slipped muscle (Parks)	Stretched scar
Muscle lacks direct attachment to sclera but is indirectly attached via loose muscle capsule	
Occurs when the muscle capsule is imbricated without including the muscle or tendon during strabismus surgery	
Noticed during immediate post-op period	

Slipped muscle (Parks)	Stretched scar (Ludwig)
Muscle lacks direct attachment to sclera but is indirectly attached via loose muscle capsule	Muscle lacks direct attachment to sclera but is indirectly attached via lengthened scar
Occurs when the muscle capsule is imbricated without including the muscle or tendon during strabismus surgery	Occurs after prior surgery involving reattachment of a rectus muscle
Noticed during immediate post-op period	Slowly progressive over months to years after surgery

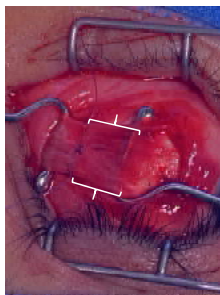
### Surgical Options

- Recess LR OU
- Strengthen MR OU
- Recess LR and Resect MR OS
- Recess LR and Resect/Advance MR OD
  - Amblyopia OD
  - Explore underacting RMR

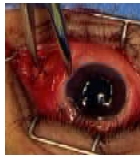
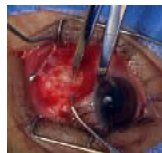
-Negative forced ductions  
-MR found at 10 mm from the limbus

scar-muscle junction



MR secured just posterior to the junction line (consider non-absorbable suture), scar excised



MR reattached at 8mm from limbus (2mm advancement)

#### Surgery:

- RLR recessed 7.0 mm with adjustable suture
- RMR resected 4.0 mm and advanced 2.0 mm (from 10.0 to 8.0 from the limbus)

#### Guidelines:

- Use standard strabismus surgical tables to determine desired resection
- Consider that 1 mm advancement is equivalent to 1 mm resection
  - 6 mm desired resection – 4 mm resection sheath/scar = 2 mm advancement
- Beware of tight muscles which may require smaller surgical dose
  - Dynamic method

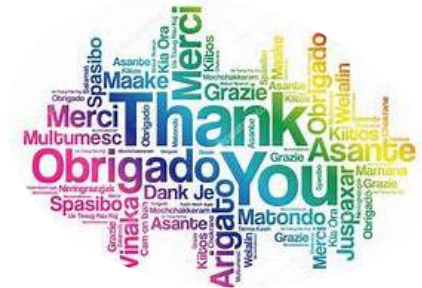

### Take Home Points

- Suspect a stretched scar in cases of strabismus:
  - late onset
  - slowly progressive
  - associated with weakness of ocular ductions
- Surgical treatment
  - excision of the scar tissue
  - possible muscle advancement
  - possible surgery of antagonist muscle

### References

- Parks MM, Bloom JN. The “slipped” muscle. *Ophthalmology*. 1979;86:1389–96.
- Ludwig IH, Chow AY. Scar remodeling after strabismus surgery. *J AAPOS*. 2000;4:326–33.
- Ludwig IH. Scar remodeling after strabismus surgery. *Trans Am Ophthalmol Soc*. 1999;97:583
- Farid, M.F., Mahmoud, M.R. & Awwad, M.A. Management of stretched scar–induced secondary strabismus. *BMC Ophthalmol* 20, 58 (2020). <https://doi.org/10.1186/s12886-020-01339-7>
- Tinley C, Evans S, McGrane D, Quinn A. Single medial rectus muscle advancement in stretched scar consecutive exotropia. *J AAPOS*. 2010;14:120–3.
- Duranoglu Y, Ilhan HD, Guler Alis M. Surgical results of the slipped medial rectus muscle after hang back recession surgery. *Int J Ophthalmol* 2014;7(6):1035-1038



Lost muscle	Slipped muscle	Stretched scar
Muscle has lost all direct or indirect connection to the sclera	Muscle lacks direct attachment to sclera but is indirectly attached via loose muscle capsule	Muscle lacks direct attachment to sclera but is indirectly attached via lengthened scar
Occurs after trauma, strabismus, sinus, orbital or retinal detachment surgery	Occurs when the muscle capsule is imbricated without including the muscle or tendon during strabismus surgery	Occurs after prior surgery involving reattachment of a rectus muscle
At time of trauma or surgery	During immediate post-op period	Slowly progressive over months to years after surgery

# **Oculoplástica**

## **Oculoplastics**

**Carcinoma Basocelular Periocular  
Grande Tratado con Vismodegib**

Large Periocular Basal Cell Carcinoma  
Treated with Vismodegib






**Dr. Brian C. Tse**

## Large Periocular Basal Cell Carcinoma Treated with Vismodegib

Brian C. Tse, M.D.





Assistant Professor of Clinical Ophthalmology  
Oculofacial Plastic & Reconstructive Surgery,  
Orbital Surgery, and Oncology

Bascom Palmer Eye Institute  
Miami, FL

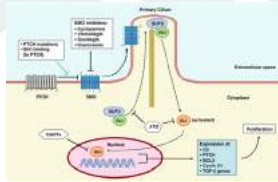
## Financial Disclosures

- None









## Hedgehog Pathway Inhibitors

- Patched (PTCH1) has inhibitory action on Smoothed (SMO)
  - Loss of function mutation in PTCH1 found in >85% of sporadic BCC and nearly all basal cell nevus syndrome
- Vismodegib is a selective small molecule inhibitor of SMO and hedgehog pathway

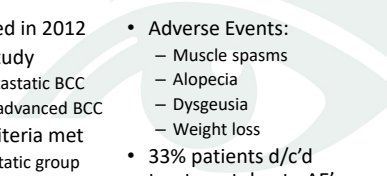





<https://link.springer.com/chapter/10.1007/978-3-319-66884-0>

## Vismodegib

- FDA approved in 2012
- ERIVANCE Study
  - 33 pts: metastatic BCC
  - 63: locally advanced BCC
- Response criteria met
  - 45% metastatic group
    - All partial response
  - 60% locally advanced
    - 21% complete response
  - Progression in only 3% and 15%, respectively
- Adverse Events:
  - Muscle spasms
  - Alopecia
  - Dysgeusia
  - Weight loss
- 33% patients d/c'd treatment due to AE's









JAMA Ophthalmology | Original Investigation

### Outcomes of Vismodegib for Periocular Locally Advanced Basal Cell Carcinoma From an Open-label Trial


Meydan Ben Ishai, MD; Akira Terasawa, MD; Eyal Feng, MD; Guy Ben Simon, MD; Ifrach Yassur, MD

- Open-label cohort study of 244 patients
- Overall response rate
  - 67.2%
  - Complete: 28.7%
  - Partial: 38.5%
- Median duration of tx:
  - 40 wks for locally advanced BCC
- 95.1% of patients had >1 adverse event
  - Mean 24.1 weeks to first moderate or severe AE
- 23.8% had to discontinue drug secondary to AD
  - 0.8% (n=2) had treatment related death










## Morpheaform BCC

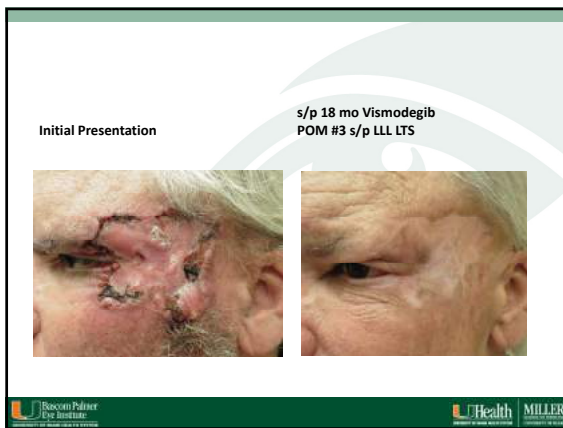
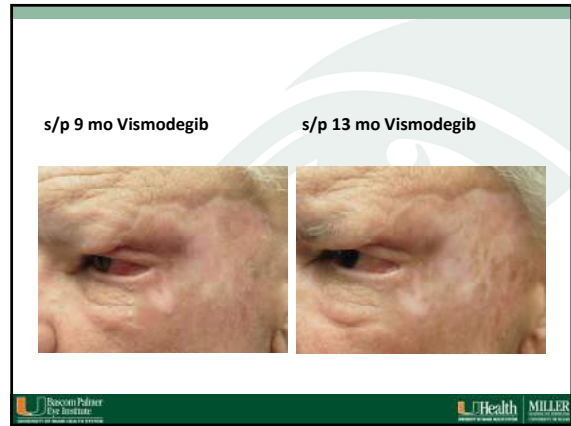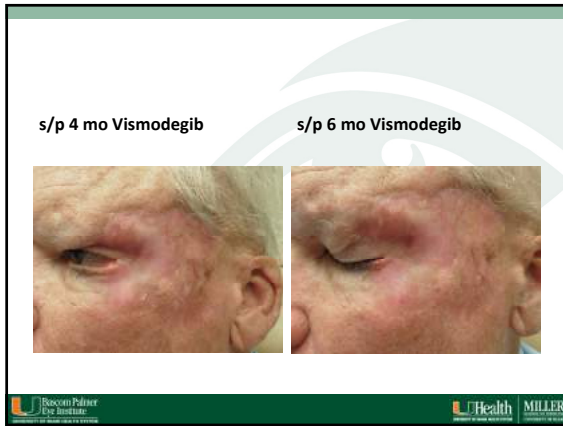Initial Presentation



s/p 1 mo Vismodegib





### Future Questions

- Duration of therapy
  - Studies suggest that small foci of viable tumor cells can recur after cessation of therapy
  - AE's usually limit duration of treatment
- Neoadjuvant use
  - Unknown at this time
  - Some promising results
    - After Vismodegib, Mohs defect found to be 27% smaller than expected
- Cost: ~\$13,000 USD for 1 month supply

Bascom Palmer Eye Institute      UHealth      MILLER

### Conclusions

- Hedgehog inhibitors (Vismodegib) can be effective for advanced periorcular BCC
- More data needed as to utility in addition to surgery

Bascom Palmer Eye Institute      UHealth      MILLER

# **Oculoplástica**

## **Oculoplastics**

**Visitando el Pasado**  
Revisiting the Past



**Dr. Andrew Rong**

## Revisiting the Past

Andrew Rong, MD  
 Assistant Professor of Oculoplastic Surgery  
 Bascom Palmer Eye Institute

- 53 year old woman presenting to BPEI with acute vision loss OS

-3 weeks

- Headache
- Diplopia
- Cloudy Vision OS

-1 week

- Complete vision loss OS
- Orbital pain OS

Neurologist started on IV steroids and transitioned to 60mg of oral prednisone  
 Improved pain, vision unchanged

- Past Medical History
  - Breast cancer, Stage 1A (no lymph node involvement)
  - Chronic sinusitis
- Past Surgical History
  - Breast lumpectomy 3 years prior
  - Sinus Surgery 7 years prior

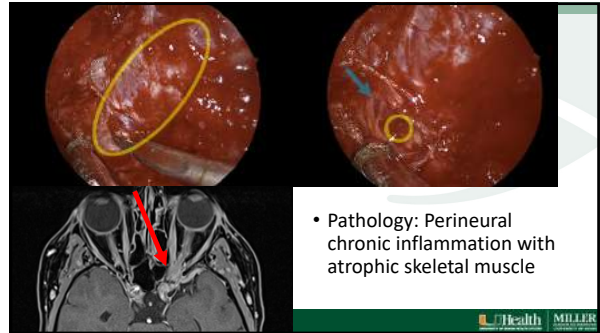
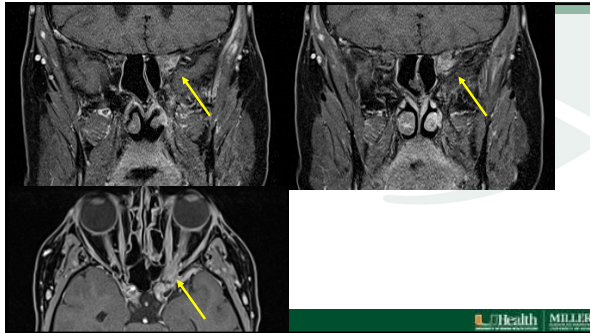
### Recent hospitalization 5 months prior to presentation

- Bronchiolitis obliterans with organizing pneumonia (BOOP)
  - Treated with immunosuppressive medication: Azathioprine and a tapering dose of oral prednisone

## Exam

Visual Acuity	
OD	20/25
OS	NLP

- +Afferent pupillary defect OS
- Extraocular motility: slight restriction in abduction OS
- Hertel equal OU



- Pathology: Perineural chronic inflammation with atrophic skeletal muscle

## Stepping back—More history taking

- 7 years ago had severe sinus disease requiring endoscopic sinus surgery.
- At the same time developed shortness of breath and was diagnosed with adult onset asthma.
- Recent hospitalization for BOOP and now presents with an inflammatory orbital mass
  - Could the pulmonary disease actually represent granulomatosis with polyangiitis

### Additional Serology:

c-ANCA: 1:80

Anti-proteinase 3 (PR-3) Abs: >100

IgG4: WNL

## Chronic pulmonary granulomatosis with polyangiitis masquerading as BOOP in a patient with orbital disease

- Our patient was started on cyclophosphamide with resolution of orbital and lung lesions. Vision never returned

### Learning Points

- Diagnoses change as disease evolves
- Remember general medicine by re-evaluate diseases outside of ophthalmology in patients with orbital disease

# **Oculoplástica**

## **Oculoplastics**

**El Otro Tumor Maligno  
de la Glandula Lacrimal**

The other Lacrimal Gland  
Malignant Tumor



**Dr. Thomas E. Johnson**

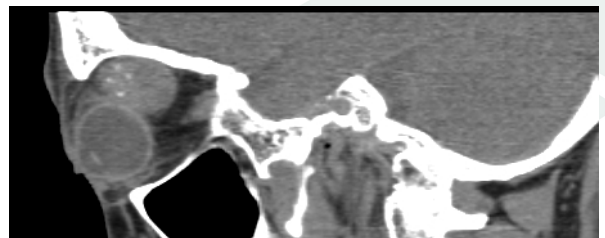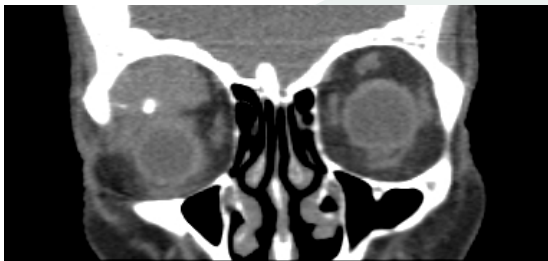
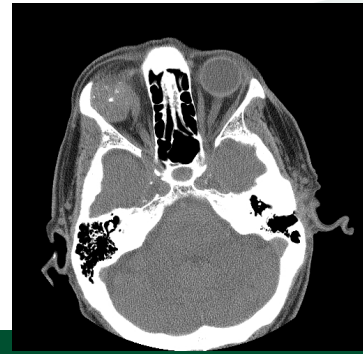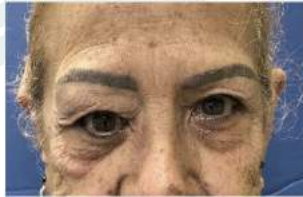# The Other Malignant Lacrimal Gland Tumor

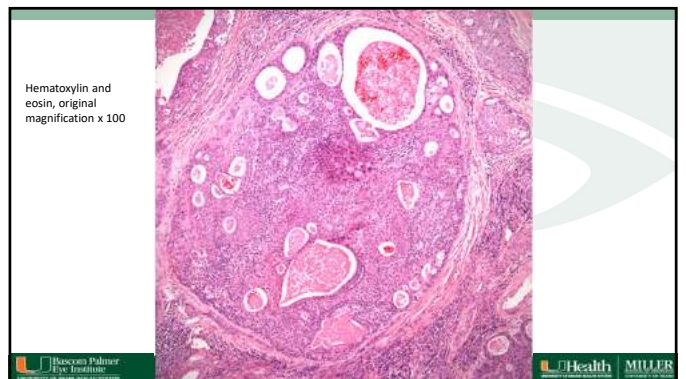
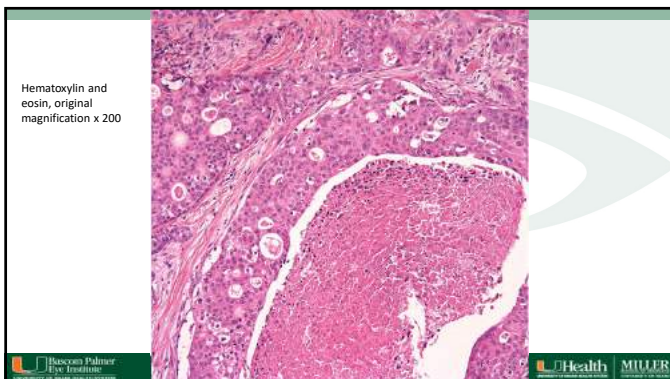
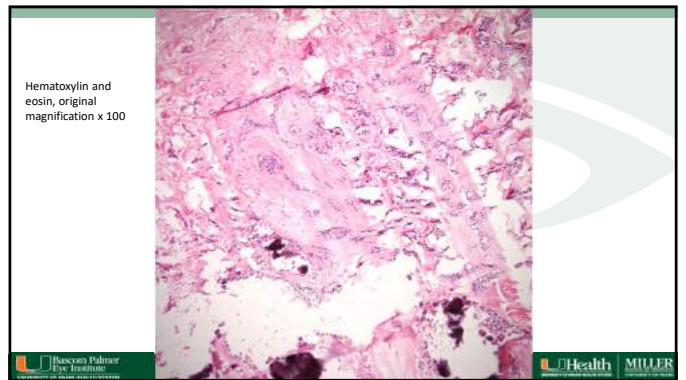
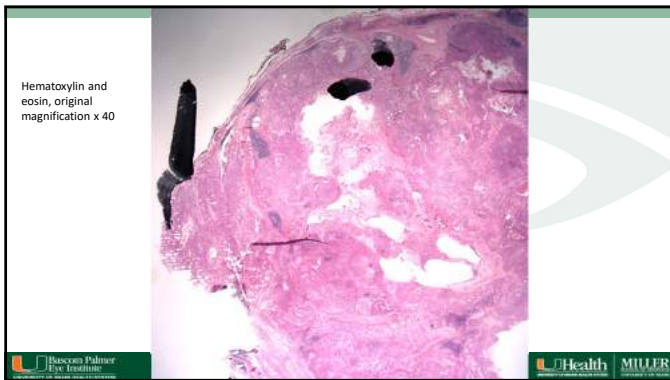
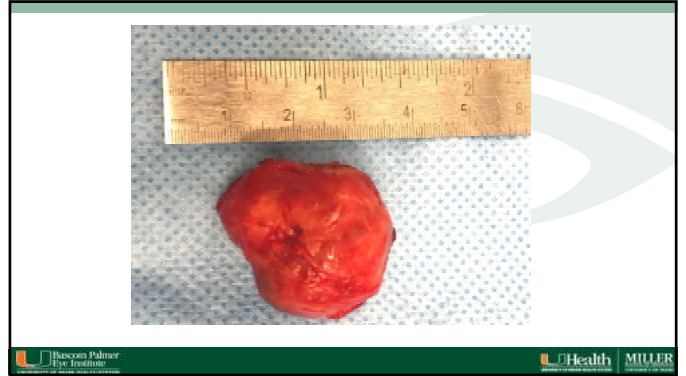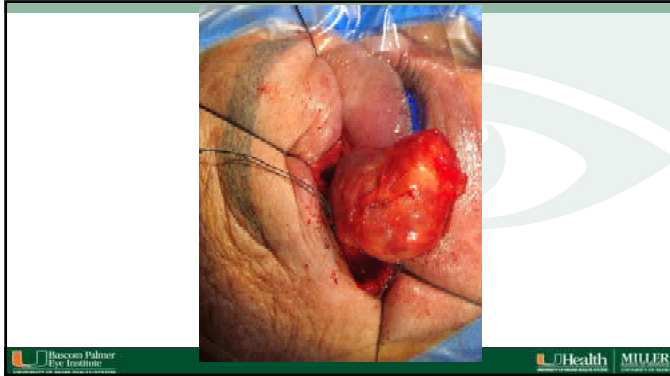
Thomas E. Johnson, MD  
Bascom Palmer Eye Institute  
University of Miami Miller School of Medicine  
CURSO 2020

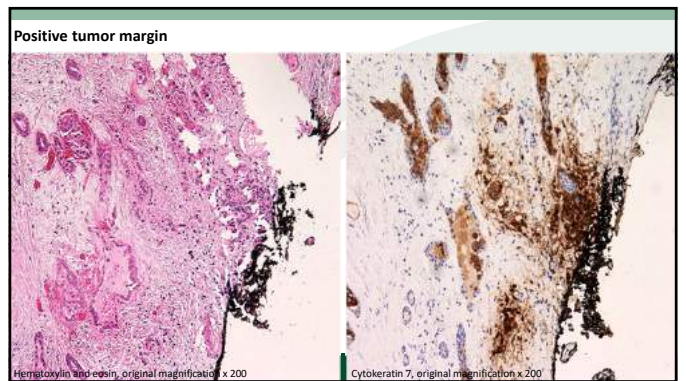
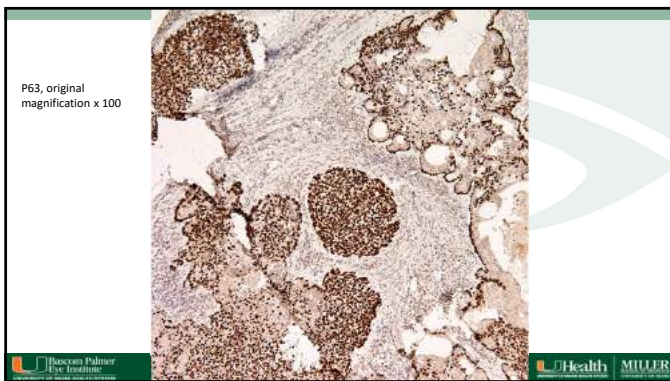
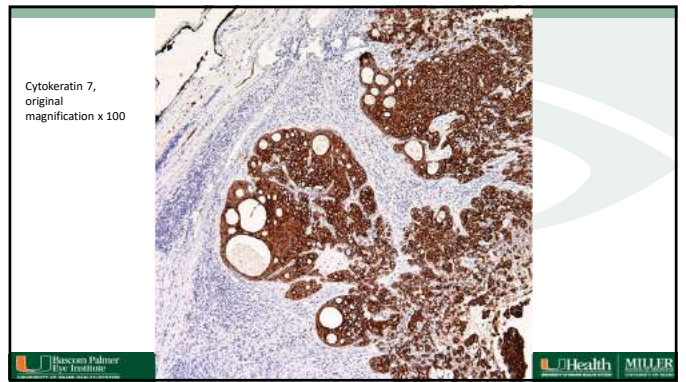
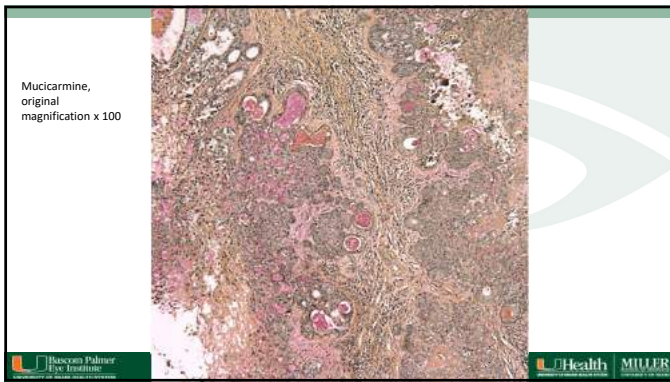
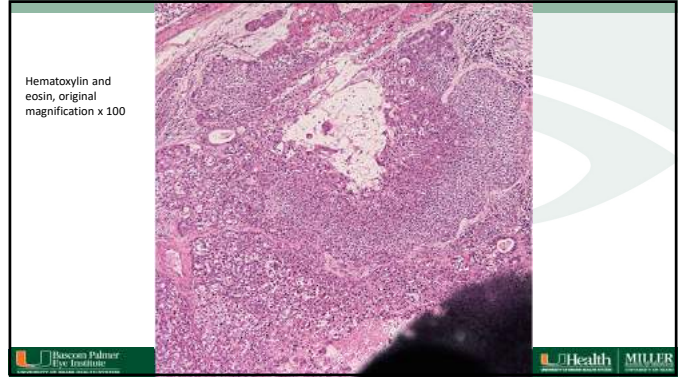
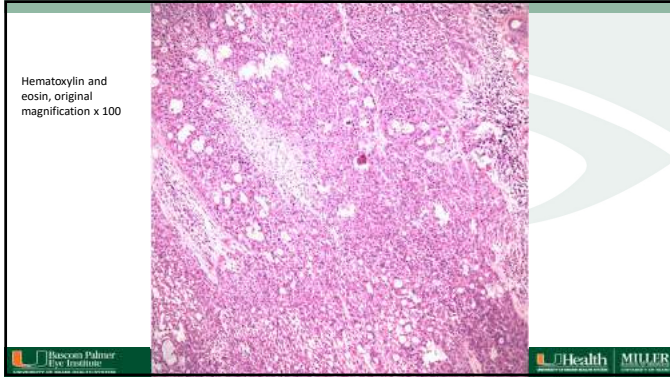
No Financial Disclosures

## Case Presentation

- 76-year-old female
- Diplopia for 6 months, denies pain
- Vision and pressure normal OU
- No APD
- Hypoglobus
- 3 mm proptosis OD







## Lacrimal Gland Tumors

- Non-epithelial (Inflammatory, lymphoid) 80%
- Epithelial 20%
  - Benign (Pleomorphic adenoma, “benign mixed tumor”) 55%
  - Malignant 45%
    - Adenoid cystic carcinoma 60%
    - Carcinoma ex-pleomorphic adenoma (Malignant mixed tumor) 20%

## Signs and Symptoms Malignancy

- Pain
- Rapid growth
- Infiltrative appearance on imaging
- Bony erosion on imaging
- **Calcifications** on imaging

## Malignant Mixed Tumor Mucoepidermoid Variant

- “Carcinoma ex pleomorphic adenoma”
- Mucoepidermoid rarest subtype
- Most occur de novo although can occur from transformation incompletely excised pleomorphic adenoma
- Salivary gland literature – just surgical excision if confined within capsule; with extracapsular extension, RT
- Ophthalmology literature limited, adjuvant chemo in most (cisplatin, carboplatin)

## Carcinoma Ex-Pleomorphic Adenoma Subtypes

- Adenocarcinoma
- Apocrine
- Myoepithelial carcinoma
- **Mucoepidermoid carcinoma** (exceedingly rare)

## Management

- No clear guidelines
- Complete excision
- If extension through capsule, radiation therapy
  - 70 gray
- PET CT and CT of neck
- Possible adjuvant chemotherapy

## Conclusions

- Some benign appearing lacrimal gland tumors are malignant
- Calcification within the mass on imaging may be a clue to malignancy
- Important to completely excise all tumors presenting as pleomorphic adenomas
- If adenoid cystic CA suspected, incisional biopsy to spare lacrimal artery and allow intracarotid chemotherapy
- Carcinoma ex-pleomorphic adenomas should undergo metastatic work-up including PET CT and neck CT, radiation therapy if capsule invaded, possible adjuvant chemotherapy

## References

- 1. Tom, ABS, Bell, D, Ford, Jr, et al, Esmaeli, B: .Malignant Mixed Tumor (Carcinoma Ex Pleomorphic Adenoma) of the Lacrimal Gland. *Ophthal Plast Recons Surg* 36: 497-502, 2020
- 2. Weis E, Rootman J, Joly TJ, et al. Epithelial lacrimal gland tumors: pathologic classification and current understanding. *Arch Ophthalmol* 2009;127:1016–1028.
- 3. White VA, Esmaeli B, Dutton JJ, et al. Amin MB. Lacrimal gland carcinoma. In: *AJCC Cancer Staging Manual*. 2017:8th ed. New York, NY: Springer, 833–839.

# **Oculoplástica**

## **Oculoplastics**

**Los Riesgos Asociados con la Inyección  
Periocular de Acido Deoxicólico para el  
Prolapso de la Grasa Orbital**


Risks Associated with Periocular Injection of  
Deoxycholic Acid for Orbital Fat Prolapse



**Dr. Bradford W. Lee**

# Risks Associated with Periocular Injection of Deoxycholic Acid for Orbital Fat Prolapse

Bradford W. Lee, MD, MSc  
 XLII Inter-American Course in Clinical Ophthalmology

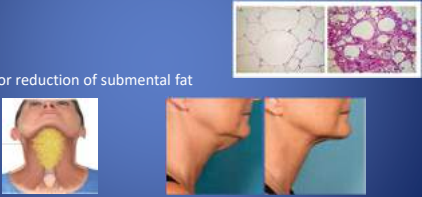



# FINANCIAL DISCLOSURE

The authors have no financial interests or relationships to disclose.

# Deoxycholic Acid (DCA)

- Endogenous bile acid that dissolves cell membranes → cell lysis
- Approved for reduction of submental fat



Reference: Jones et al, *Derm Surg* (2015), Odo et al, *Derm Surg* (2007)

### Table 1. Adverse Reactions in the Pooled Trials 1 and 2\*

Adverse reactions	SYMBELLA® (n=511)	Placebo (n=509)
Injection site reactions	467 (91%)	411 (81%)
erythema/swelling	404 (79%)	334 (66%)
pain	394 (77%)	363 (71%)
pruritus	311 (61%)	204 (40%)
erythema	176 (35%)	111 (22%)
swelling	176 (35%)	132 (26%)
paresthesia	78 (15%)	20 (4%)
itch	66 (13%)	24 (5%)
pain	64 (13%)	30 (6%)
skin tightness	24 (5%)	6 (1%)
skin numbness	24 (5%)	2 (0%)
skin redness	22 (4%)	1 (0%)
itch	11 (2%)	2 (0%)
headache	11 (2%)	2 (0%)
conjunctival pain	11 (2%)	1 (0%)
hyperemia	11 (2%)	1 (0%)
nausea	11 (2%)	1 (0%)
dizziness	10 (2%)	1 (0%)

Reference: website [www.allergan.com/assets/pdf/kybella\\_pi](http://www.allergan.com/assets/pdf/kybella_pi); El-Gowelli et al, *Exper Toxicol Pathol* (2015).

- Injected to mouse inguinal region*
- Skeletal muscle necrosis/fibrosis
  - Myelin and axonal degeneration
  - Vasculitis w/ smooth muscle injury

# DCA Used Off-Label to Treat Orbital Fat Prolapse

- Derm Surg*, 2004  
**Treatment of Lower Eyelid Fat Pads Using Phosphatidylcholine: Clinical Trial and Review**  
GLAYSON, MARLENE, MD, FACP; ADAMI, SE, MD, FRCPC, FRCPC  
\*First Use: Angioma Network; Administrative Medical Center and Division of Dermatology, David Geffen School of Medicine, University of California at Los Angeles, Los Angeles, California
- Derm Surg*, 2001  
**The Use of Phosphatidylcholine for Correction of Lower Lid Bulging Due to Prominent Fat Pads**  
BARBARA SCHEIDT BETHKE, MD  
Clinical Practice Review, San Pedro, Puerto Rico



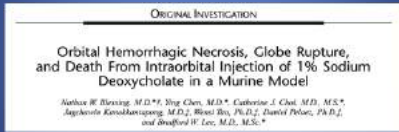
**Deoxycholic Acid Injections for the Treatment of Infraorbital Fat Pads**  
 Lindsey, Scott F.; Benesh, Gabrielle.; Pavlis, Janellie.; Zalac, Martin  
 PHILADELPHIA: by the American Society for Dermatologic Surgery, Inc. Published by Wolters Kluwer Health, Inc. All rights reserved  
 Dermatologic surgery, 2019-12, Vol.45 (12), p.1720-1723

# Potential Adverse Effects from Periocular/Intraorbital Use

- Muscle degeneration/necrosis?
- Demyelination/degeneration of sensory and motor nerves?
- Vasculitis/hemorrhage?
- Damage to ocular tissues, glands, fat, ocular adnexa?
- Orbital compartment syndrome?

## Study Aim

- Determine effects of intraorbital and periocular injection of DCA



Ophthalmic Plast Reconstr Surg, 2020 (Published ahead of print)

## Methods

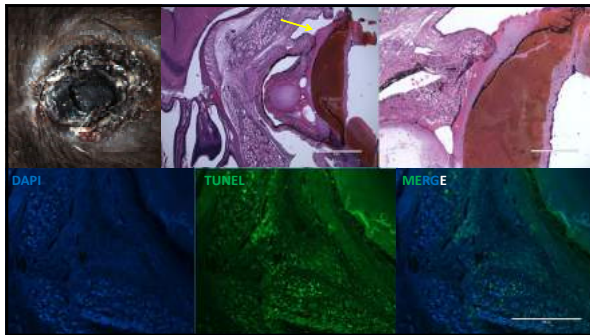
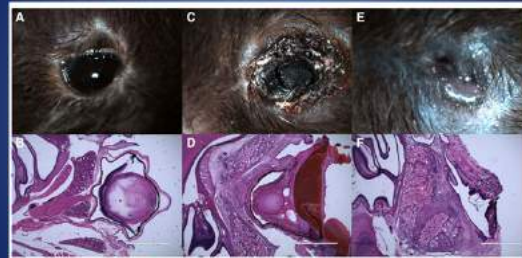
- Animal model: C57BL/6J adult mice
- Protocol: clinical photos, histology at sacrifice after 1-7 days
- Injections performed with 31g needle



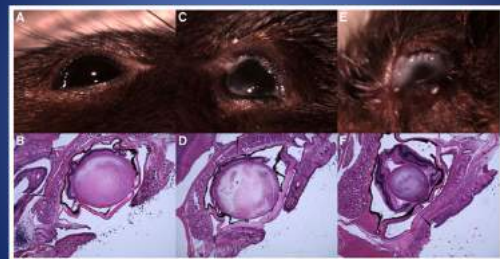
Study treatments and outcomes				
Mouse	Sex	Treatment	Status post-injection	Histopathology
1	XX	1% PBS (control)	Alive	Normal
2	XX	1% PBS (control)	Alive	Normal
3	XX	1% PBS (control)	Alive	Normal
4	XX	1% DCA (PBS)	Alive	Normal
5	XX	1% DCA (PBS)	Alive	Globe rupture, hemorrhagic necrosis, glial inflammation
6	XX	1% DCA (PBS)	Alive	Globe rupture, hyphema
7	XX	1% DCA (PBS)	Deceased	
8	XX	1% DCA (PBS)	Deceased	
9	XX	1% DCA (PBS)	Deceased	
10	XX	1% DCA (PBS)	Deceased	
11	XX	1% DCA (PBS)	Deceased	
12	XX	1% DCA (PBS)	Deceased	
13	IF	1% DCA (PBS)	Deceased	
14	IF	1% DCA (PBS)	Alive	Retinal hemorrhage with glial collapse, severe retinal inflammatory necrosis (day 1)
15	IF	0.5% DCA (PBS)	Alive	Intraorbital hemorrhage with glial collapse and inflammatory necrosis (day 3)
16	IF	0.5% DCA (PBS)	Alive	Normal
17	IF	0.5% DCA (PBS)	Alive	Conjunctival opacification, proptosis, glaucoma inflammation, mild vitreal hemorrhage
18	IF	0.5% DCA (PBS)	Alive	Normal
19	IF	0.25% DCA (PBS)	Alive	Mild periorbital edema
20	IF	0.25% DCA (PBS)	Alive	Hemorrhage 2 days after injection, protracted inflammatory necrosis with no clinical globe after 7 weeks
21	IF	0.25% DCA (PBS)	Alive	Normal
22	IF	0.25% DCA (lower lat)	Alive	Soft tissue inflammatory necrosis, eyelid edema, occlusion
23	IF	0.25% DCA (lower lat)	Alive	Soft tissue inflammatory necrosis, eyelid edema

PBS, phosphate buffered saline.

## Late globe rupture and degeneration



## SubQ Injection to Eyelid



## Conclusions

- DCA causes robust inflammatory necrosis of various tissue types.
- Periocular injection can cause devastating orbital and ocular degeneration in a mouse model.
- Extreme caution is advised for off-label use in periocular region.

## Acknowledgements

- Co-authors: Nathan Blessing, Ying Chen, Catherine Choi, Jugchawin Kanokkantung, Wensi Tao, and Daniel Pelaez
- Rashid Orbital and Vision Research Center

## References

1. Ablon G, Rotunda AM. Treatment of lower eyelid fat pads using phosphatidylcholine: clinical trial and review. *Dermatol Surg* 2004;30(3):422-7; discussion 8.
2. Jones DH, Carruthers J, Joseph JH, Callender VD, Walker P, Lee DR, Subramanian M, Lizzuf PF, Gross TM, Beddingfield FC 3rd. REFINÉ-1, a Multicenter, Randomized, Double-Blind, Placebo-Controlled, Phase 3 Trial With ATX-101, an Injectable Drug for Submental Fat Reduction. *Dermatol Surg*. 2016 Jan;42(1):38-49.
3. Yagima Odo ME, Cuce LC, Odo LM, Nattrelli A. Action of sodium deoxycholate on subcutaneous human tissue: local and systemic effects. *Dermatol Surg* 2007;33(2):178-88; discussion 88-9.
4. Rittes PG. The use of phosphatidylcholine for correction of localized fat deposits. *Aesthetic Plast Surg* 2003;27(4):315-8.
5. Rittes PG. The use of phosphatidylcholine for correction of lower lid bulging due to prominent fat pads. *Dermatol Surg* 2001;27(4):391-2.
6. El-Gowelli HM, El Sabaa B, Yosry E, El-Saghir H. Histopathological and ultra-structural characterization of local neuromuscular damage induced by repeated phosphatidylcholine/deoxycholate injection. *Exp Toxicol Pathol* 2016;68(1):39-46.
7. Yardeni T, Eckhaus M, Morris HD, et al. Retro-orbital injections in mice. *Lab Anim (NY)* 2011;40(5):155-60.

Thank You

Bradford W. Lee, MD, MS  
Email: blee@miami.edu



# **Oculoplástica**

## **Oculoplastics**

**Piensa Dos Veces – Manejo de una  
Lesión Desafiante del Nervio Óptico**

**Think Twice – Managing a Challenging  
Optic Nerve Lesion**



**Dr. Chris R. Alabiad**

# Think Twice! Managing a challenging optic nerve lesion

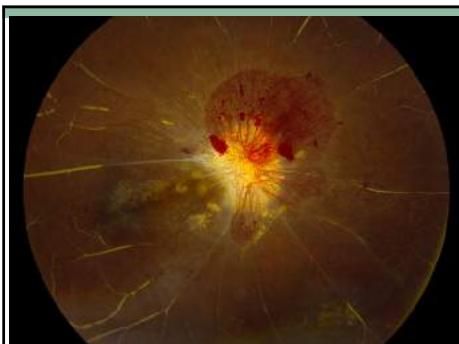
Chris Alabiad, MD  
Associate Professor of Clinical Ophthalmology  
Bascom Palmer Eye Institute  
University of Miami, Miller School of Medicine

## Case

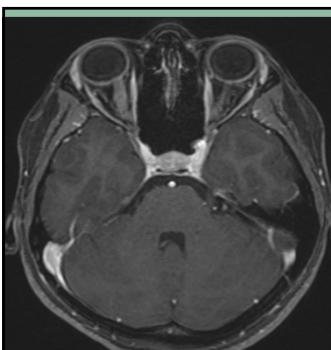
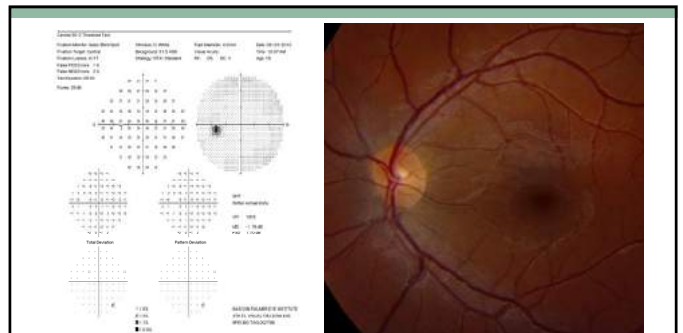
An 18 year old woman presents with an 8 week history of vision loss in the right eye. She seeks a second opinion after management in South America.

Examination upon arrival to BPEI:

- **Vision**  
OD: CF  
OS: 20/15
- **Pupils**  
Right rAPD
- **Extraocular Motility**  
Full OU



- CRAO
- CRVO
- Optic Nerve edema
- Neovascularization
- Cotton Wool Spots



Impression:  
Changes of right optic nerve characteristic of optic neuritis, but no evidence of white matter or demyelinating lesions in the brain. Need clinical and laboratory correlation.

## Laboratory and Imaging Workup

- ESR, CRP
- ACE
- ANA
- NMO
- RPR and FTA-ABS
- PPD
- Bartonella titers
- Lyme titers
- Toxoplasma/Toxocara
- Ca-125, CEA, AFP
- Paraneoplastic panel
- Anti-Cv2
- Cryoglobulins
- HLA-B7, HLA-B-27
- Ant-streptolysin
- Anti-DNA, SSA and SSB
- Anti-cardiolipin
- Complement C3
- CMV, HIV, HbsAG

### Imaging

- MRI cervical, spine,
- Mammogram
- CT-scan chest, abdomen, and pelvis

**ALL NORMAL**

### Optic nerve and Sheath biopsy

Chronic inflammatory infiltrates and changes  
No pathological diagnosis!!!

GLOBAL CENTER FOR OPTIC NERVE REGENERATION  
bascompalmer.org

- Suspicion for underlying pathology was so high that a craniotomy was performed to obtain an intracranial biopsy of the optic nerve.

GLOBAL CENTER FOR OPTIC NERVE REGENERATION  
bascompalmer.org

### Clinical Pathology

Intracranial portion of the right optic nerve specimen

KI-67, 100x      IDH1, 100x      P53, 200x

-The Ki67 index of the posterior margin of the tissue was 4-5%  
- Olig and IDH1 stains negative; weak p53 staining

Anaplastic Astrocytoma WHO Grade III

GLOBAL CENTER FOR OPTIC NERVE REGENERATION  
bascompalmer.org

### Management

- The entire intraorbital and intracranial portion of the lesion was removed with microscopic positive margins just anterior to the chiasm
- The patient underwent chemotherapy (6 month course of temozolomide) and radiation (60 Gray in 30 fractions)

GLOBAL CENTER FOR OPTIC NERVE REGENERATION  
bascompalmer.org

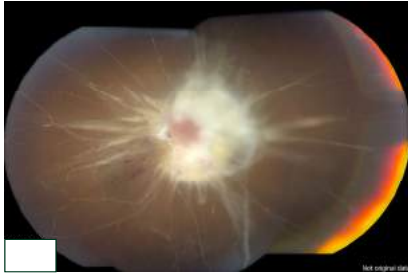### 5 months after surgery

GLOBAL CENTER FOR OPTIC NERVE REGENERATION  
bascompalmer.org

### 9 months after surgery

GLOBAL CENTER FOR OPTIC NERVE REGENERATION  
bascompalmer.org

## 1 year after surgery




## Now what?

- The Eye was enucleated for fear of extension of disease into the globe.
- Pathology was negative
- Patient has been cancer free since (over 7 years!)

## Conclusions

- Determining the etiology of the underlying optic nerve mass can be made via biopsy, however, a negative biopsy may not indicate absence of disease...**Think Twice!!**
- Early recognition and appropriate treatment can prevent vision loss and save lives.

## Thank you!



# Oculoplástica

## Oculoplastics

**Mapeo Automatizado, sin Contacto, de Topografía Facial, Impresión Tridimensional y Fundición de Silicona de Prótesis Orbitaria**

Automated Noncontact Facial Topography Mapping, 3-Dimensional Printing, and Silicone Casting of Orbital Prosthesis




**Dr. David T. Tse**

UNHEALTH INTERNATIONAL  
 3-D Printing for Exenteration Prosthesis

David T. Tse, M.D., F.A.C.S  
 Nasser Ibrahim Al-Rashid Orbital  
 Vision Research Center

Department of Ophthalmology  
 Bascom Palmer Eye Institute



UNHEALTH INTERNATIONAL  
 Orbital Prosthesis Fitting  
 3-6 months after surgery




UNHEALTH INTERNATIONAL  
 Conventional Fabrication Process




Shrestha B, Goveas R, Thawornurita S. *Hand fabrication of silicone orbital prostheses using conventional methods*. Singapore Dent J. 2014; Dec;36:83-6. doi: 10.1016/j.sdg.2014.10.002. PubMed PMID: 25486991.




UNHEALTH INTERNATIONAL  
 Challenges

- Orbital prosthesis fabrication is a costly, time-intensive
- Limited number of trained ocularist
- Access to orbital prostheses is limited by proximity to a prosthetist
- Expensive manual fabrication process - \$5,000 - \$15,000
- Insurance may not cover device
- Replacement – financial burden




UNHEALTH INTERNATIONAL  
 Workflow

- Automated
- Non-contact facial topography mapping
- 3-D printing
- Silicone casting of orbital prosthesis



UNHEALTH INTERNATIONAL  
 1. Facial Topography Mapping

## 2. Artec raw data imported to CAD software Geomagic Design

UNHEALTH INTERNATIONAL  
UNIVERSITY OF HEALTH SCIENCES

Iranian Polymer  
Institute for Biomedical  
Engineering

## 3. Digital Sculpting of Orbital Prosthesis

The mirrored version of the contralateral periorbital region is merged with the orbital defect scan, enabling the surfaces to be meshed to define the shape of the prosthesis.

merge  
mirror  
mesh

UNHEALTH INTERNATIONAL  
UNIVERSITY OF HEALTH SCIENCES

Iranian Polymer  
Institute for Biomedical  
Engineering

## 4. Prosthetic Design

**CONTOURS**

Defect side Facial surface  
Socket/Defect  
Unaffected side Facial surface

**3-D DIGITAL MODEL**

UNHEALTH INTERNATIONAL  
UNIVERSITY OF HEALTH SCIENCES

Iranian Polymer  
Institute for Biomedical  
Engineering

## 6. Printing of Digitally Designed 3D Mold

Material: ABS  
Layer Resolution: 60 um  
Print time: 15-20hr

20 hours

UNHEALTH INTERNATIONAL  
UNIVERSITY OF HEALTH SCIENCES

Iranian Polymer  
Institute for Biomedical  
Engineering

## 7. Elastomer preparation

- Spectro-colorimeter to obtain 6-8 measurements of skin tone.
- Based on RGB readout, different pigments are mixed according to standardized color palette developed in-house for silicone coloring
- A biocompatible elastomer (Silicone Shore 35) mixed with a custom blend of pigment to approximate patient's skin tone.
- Mixture homogenized and de-gassed using speed mixer
- Red flocking fibers are added to simulate surface micro vasculature

UNHEALTH INTERNATIONAL  
UNIVERSITY OF HEALTH SCIENCES

Iranian Polymer  
Institute for Biomedical  
Engineering

## 8. Casting of the Prosthesis

- Silicone (Shore 35) allowed to cure overnight - 16 hours.
- De-molding of base-tone matched prosthesis

UNHEALTH INTERNATIONAL  
UNIVERSITY OF HEALTH SCIENCES

Iranian Polymer  
Institute for Biomedical  
Engineering

**UNHEALTHY INTERNATIONAL**

## Detailing

- Extrinsic coloring (shading) painted in by hand
- Eyelashes affixed using silicone glue
- Surface sealed with silicone sealant
- Ocular piece fitted




**Bascom Palmer Eye Institute**  
UNIVERSITY OF MIAMI HEALTH SYSTEM

**UNHEALTHY INTERNATIONAL**

## Final Outcome

Current solution: Eye Patch      Prosthesis      Final outcome



**"This is the most comfortable prosthetic I have ever tried, I am thrilled with the outcome"**

**Bascom Palmer Eye Institute**  
UNIVERSITY OF MIAMI HEALTH SYSTEM



## THANK YOU

**Bascom Palmer Eye Institute**  
UNIVERSITY OF MIAMI HEALTH SYSTEM

# **Neuro Oftalmología**

## **Neuro Ophthalmology**

**Patrones de OCT (Tomografía de Coherencia Óptica) de la Pérdida del Complejo Ganglionar Celular en Neuro-oftalmología**

OCT Patterns of Ganglion Cell Complex Loss in Neuro-Ophthalmology



**Dr. Carlos E. Mendoza**

# Neuro-Ophthalmology Case Presentation "Hiding Behind"

**Carlos E. Mendoza-Santesteban, MD**

Assistant Professor of Clinical Ophthalmology  
Bascom Palmer Eye Institute,  
University of Miami Miller School of Medicine



bascompalmer.org

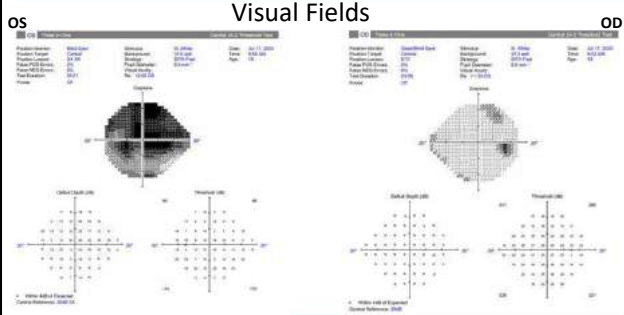
## History and Exam

- 18 y/o Caucasian female complaining of progressive blurry vision, left eye, since 4 months.
  - Seen by at least two ophthalmologists in the community.
  - Referred to rule out retinal disease
  - Headaches, since 4-5 months
  - No other significant Hx
- BCVA: OD 20/20, OS 20/100
- Visual Fields: Relative central scotoma OS (confrontation)
- Pupils: PERRLA, mild APD OS
- Extra-ocular: Full, ortho



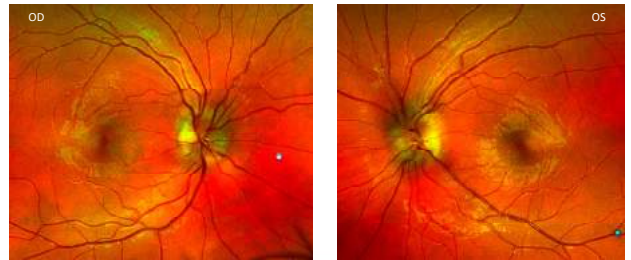
bascompalmer.org

## Visual Fields




bascompalmer.org

## Fundus Photos

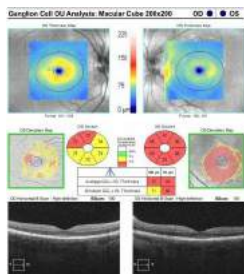


bascompalmer.org

## OCT RNFL

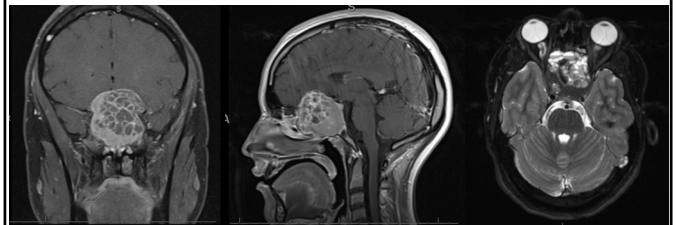


## OCT GCC



bascompalmer.org

## MRI



bascompalmer.org

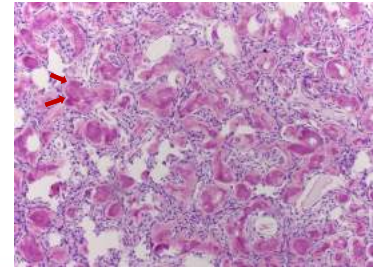
## Differential Diagnosis of Anterior Skull Base Tumors

Tumors arising from below		Tumors from above
Sinonasal neoplasms	Orbital tumors	
Squamous cell carcinoma	Lacrimal gland neoplasms	Olfactory groove meningioma
Adenocarcinoma	Neurogenic tumors	Subfrontal schwannomas
Minor salivary gland neoplasms	Lymphoma	<b>Pseudotumors:</b>
Esthesioneuroblastoma	Rhabdomyosarcoma	Mucoceles
Lymphoma	Chloroma	Sinonasal polyposis
Melanoma	Metastasis	Abscesses
Mesenchymal tumors		Fungal infection
		Osteomyelitis
		Wegener's granulomatosis

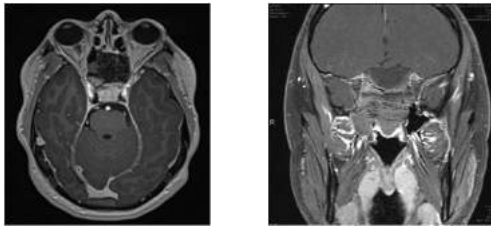
## Endonasal Approach

Histology:

Juvenile Psammomatoid  
Ossifying Fibroma



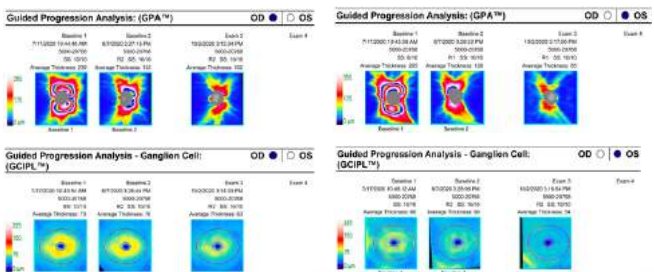
## MRI Post Op



## Visual Fields



## OCT Follow-Up



## Take Home Points

- Early loss of GCC can be seen from chiasmal compression even with minimal visual field loss.
- RNFL and GCC progression analysis is useful in monitoring optic nerve edema in compressive optic neuropathies.

Thanks



## Neuro-Ophthalmology Panel

Byron Lam, MD  
Josh Pasol, MD  
Carlos Mendoza, MD

## **Patrones de OCT (Tomografía de Coherencia Óptica) de la Pérdida del Complejo Ganglionar Celular en Neuro-oftalmología**

Dr. Carlos E. Mendoza

Diferentes tipos de neuropatía óptica causan distintos patrones de pérdida del complejo ganglionar celular (GCC por las siglas en inglés) que pueden detectarse con tomografía de coherencia óptica (OCT por las siglas en inglés). Estos usualmente reflejan patrones asociados de anomalías en el campo visual, pero pueden verse con un cambio mínimo en el campo visual. Además, los hallazgos OCT son objetivos, fáciles de obtener y más confiables que los campos visuales. En la neuropatía óptica isquémica anterior (AION por las siglas en inglés) y neuritis óptica (ON por las siglas en inglés), los cambios GCC son distintivos y pueden verse en ojos previamente afectados pero asintomáticos. Hemos demostrado que la pérdida GCC objetivamente ayuda a monitorear y pronosticar la pérdida de la vista por causa del papiledema. En la neuropatía óptica compresiva, los cambios GCC pueden verse antes de que hay pérdida significativa del campo visual, o una vez que se haya recuperado el campo visual después de la descompresión. En Leber, la pérdida GCC en la neuropatía óptica hereditaria ocurre poco después de presentarse los síntomas visuales, usualmente más temprano que la neuritis óptica retrobulbar. Los cambios GCC en la Disautonomía Familiar (Riley-Day) y Charcot-Marie Tooth (CMT por las siglas en inglés) son típicos de otras neuropatías mitocondriales. Los cambios en GCC y RNFL (capa de fibras del nervio retiniano, por las siglas en inglés) podrían ser biomarcadores preclínicos de la enfermedad de Parkinson (PD por las siglas en inglés) y atrofia de sistemas múltiples (MSA por las siglas en inglés). Se pueden utilizar los hallazgos OCT como extremos finales para los ensayos clínicos y estudios de neuro protección en la enfermedad de Parkinson. Se utilizarán ejemplos de casos para ilustrar estos hallazgos.

### **OCT Patterns of Ganglion Cell Complex Loss in Neuro-Ophthalmology**

Carlos E. Mendoza, MD

Different types of optic neuropathy cause distinctive patterns of ganglion cell complex (GCC) loss that are detectable with optical coherence tomography (OCT). These usually reflect associated patterns of visual field abnormalities, but they may be seen with minimal change in the visual field. Furthermore, OCT findings are objective, easy to obtain and more reliable than visual fields. In anterior ischemic optic neuropathy (AION) and optic neuritis (ON) the GCC changes are distinctive and may be seen in previously affected but asymptomatic eyes. We have demonstrated that GCC loss objectively helps to monitor and predict visual loss from papilledema. In compressive optic neuropathy, GCC changes may be seen before there is significant visual field loss, or after recovery of visual field following decompression. In Leber hereditary optic neuropathy GCC loss occurs very soon after visual symptoms begins, usually sooner than after retrobulbar optic neuritis. GCC changes in Familial Dysautonomia (Riley-Day) and Charcot-Marie-Tooth (CMT) are typical of other mitochondrial optic neuropathies. GCC and RNFL changes may be preclinical biomarkers for Parkinson's disease (PD) and multiple system atrophy (MSA). OCT findings may be used as reliable endpoints for clinical trials and neuroprotection studies in PD. Case examples will be used to illustrate these findings.

**Neuro Oftalmología**  
**Neuro Ophthalmology**

**No Pierdas los Nervios**  
**Don't Lose your Nerve**



**Dr. Byron L. Lam**

## Don't Lose Your Nerve

Byron L. Lam MD  
Bascom Palmer Eye Institute

No Disclosures Relevant to This Presentation



## 36-year-old man

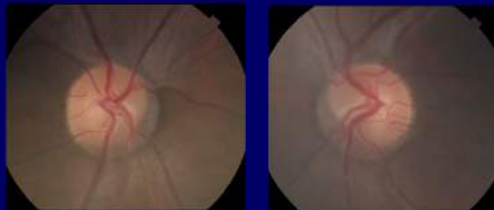
- Acute visual loss OD, blurred vision OS for 1 day
- Severe periorbital pain OU with eye movement
- OD: NLP
- OS: 20/70
- Amaurotic pupil OD

## 36-year-old man

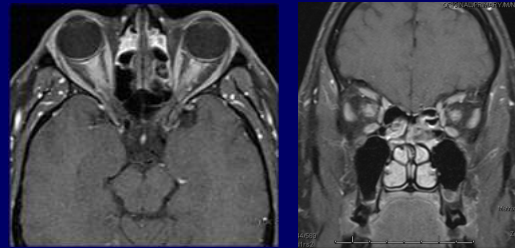
NLP OD, 20/70 OS

NLP

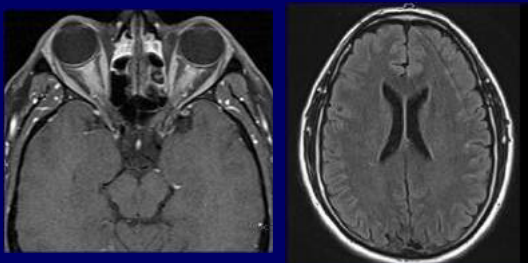
20/70



## 36-year-old man with NLP OD, 20/70 OS



## 36-year-old man with NLP OD, 20/70 OS



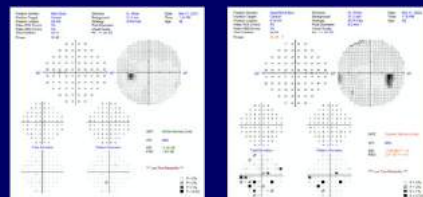
Diagnosis: Bilateral Optic Neuritis

No viral prodrome, No neurologic symptoms

## 36-year-old man with Optic Neuritis OU

NLP OD, 20/70 OS

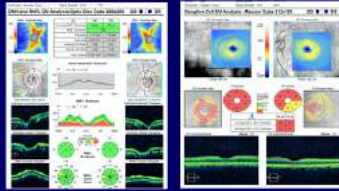
- Methylprednisolone IV 1 gm daily x 7 days
- Improved to 20/20 OU



- Prednisone 80 mg daily continued, then tapered

36-year-old man with Optic Neuritis OU  
2 weeks later

- Pain and decreased vision over 2 days.
- OD back to NLP



- Orbit MRI repeated: Optic nerve OD remains enhanced

36-year-old man with Optic Neuritis OU  
OD recurrent NLP

- Methylprednisolone IV 1 gm daily x 7 days
- Improved to blurred 20/20

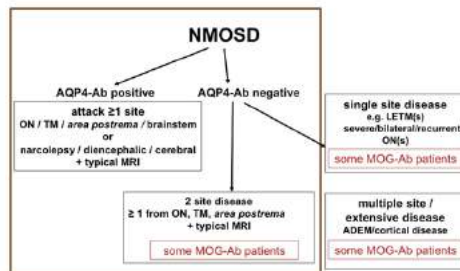
36-year-old man with Optic Neuritis OU

- Aquaporin-4 antibody – negative
- Anti-MOG positive 1:10 – delayed due to insurance
- IVIG loading then IVIG continued monthly
- Anti-MOG 6 weeks later became negative

MOG (Myelin Oligodendrocyte Glycoprotein) IgG  
Associated Disorders (MOGAD)

- CNS demyelinating disease
  - Optic neuritis – unilateral vs bilateral severity varies, recurrence common
  - Transverse myelitis
  - Acute disseminating encephalomyelitis (ADEM) – more in children
  - Brainstem encephalitis

Diagnostic criteria in Seronegative NMOSD



Optic Neuritis – Take Home Message

- Orbital MRI with GAD with brain FLAIR to assess MS risk
- IV steroid treatment based on severity, Consider plasmapheresis in steroid resistant cases
- Check Aquaporin-4 and anti-MOG antibodies – may be initially negative and repeat in 2 to 4 months, may improve with treatment
- Initiate appropriate long term preventive treatment – for MOG, IVIG every 3 to 4 weeks most effective and better than rituximab
- Consider LHON and other causes when clinical courses are not typical

# **Neuro Oftalmología**

## **Neuro Ophthalmology**

**Lección Aprendida de un Joven de  
21 años con Neuropatía Óptica**

**Lesson Learned from a 21-Year-Old  
with an Optic Neuropathy**



**Dr. Joshua Pasol**

# Lesson learned from a 21-year-old with an optic neuropathy

JOSHUA PASOL M.D.  
NEURO-OPHTHALMOLOGY  
BPEI

## Case history

- 21-year-old woman presented visual loss left eye
- She noted left eye visual loss in 2017
- Painless
- In 2017, left eye vision was 20/40 OS, APD noted, visual field showed central scotoma extending superior and optic nerve pallor/optic nerve drusen.
- MRI was done and optic neuritis was diagnosed
- 1 gram solumedrol was for 3 days was given as well as oral taper
- She noted no improvement to her vision

## Case history continued

### LABORATORY TESTING

- Cardiolipin antibody negative
- ANA negative
- Sjogren's Abs, SSA, SSB negative
- Double stranded DNA negative
- Angiotensin converting enzyme negative
- Neuromyelitis Optica antibody negative

### LUMBAR PUNCTURE

- OP 25cc
- CSF glucose: 53
- CSF protein: 35.9
- CSF ACE: 11 (< =15 U/L)
- MBP CSF: <2.0 (0 - 4.0 mcg/L)
- Oligo Bands CSF: No bands
- West Nile: negative

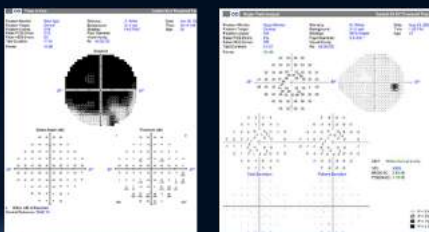### LUMBAR PUNCTURE (CONTINUED)

- California encephalitis virus antibody: negative
- Eastern Equine encephalitis virus ab: negative
- St Louis Encephalitis virus ab: negative
- Western Equine Encephalitis virus ab: negative

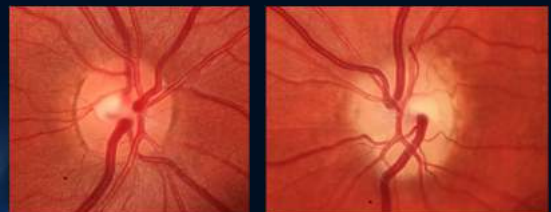
## Case history April 2020

- The patient came for exam April 2020
- She reports worsening painless vision in the left eye
- Exam:
  - Visual acuity: OD 20/20, OS count fingers at one foot
  - APD OS
  - Visual fields: see next page
  - EOMS full

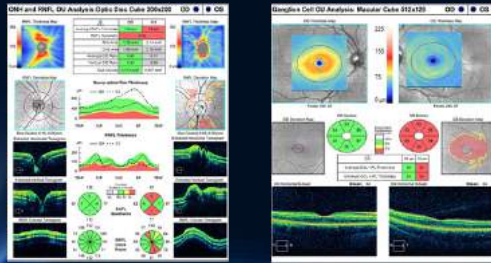
## Humphrey visual fields



## Optic disc photos



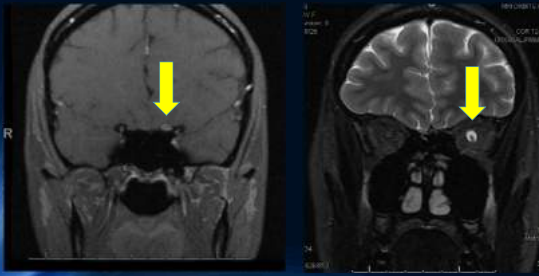
### Retinal nerve fiber layer and ganglion cell layer/inner plexiform layer OCT



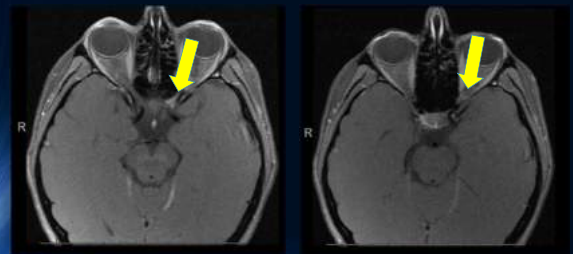
### Management

- An MRI orbits and brain was ordered
- 1 gram solumedrol was given for 3 days
- Patient followed up without visual improvement
- MRI was repeated and reported as optic neuritis

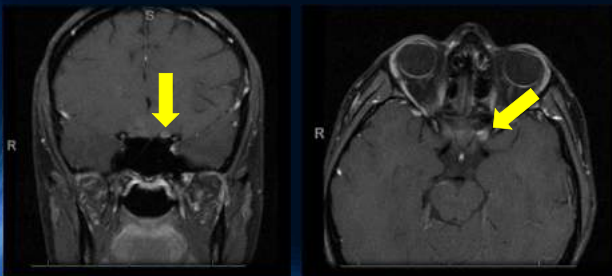
### MRI orbits 2020



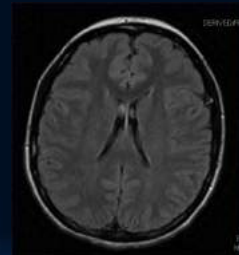
### MRI orbits 2020



### MRI orbits 2017



### MRI Brain FLAIR 2017



### Case summary so far:

- 21 year old with left eye optic neuropathy diagnosed 2017.
- Visual loss is progressive
- MRI 2017 and 2020 showed similar results
- Suspected compressive optic neuropathy, less likely inflammatory
- The patient under went a procedure

### Craniotomy performed

- Surgical Pathology:
  - "microsurgical removal of optic nerve sheath, extra-axial tumor WHO grade 1 meningioma".

### Diagnosis: optic canal meningioma in a 21-year-old female

- Meningiomas are typically benign tumors originating from the meninges.
- Meningioma location determines how it affects vision.
- Optic canal meningioma can be difficult to diagnose as they are often misdiagnosed as optic neuritis.
- Jackson et. al reported 6 cases of misdiagnosed optic canal meningiomas initially diagnosed as optic neuritis in part to inappropriate imaging quality (Jackson A et al. Intracanalicular optic nerve meningioma: a serious diagnostic pitfall. AJNR Am J Neuroradiol. 2003) .
- One must suspect compressive optic neuropathy in progressive visual loss that does not behave like classic inflammatory optic neuropathy.

## Optic canal meningioma causing progressive unilateral visual loss in a young adult

THANK YOU

# **Uveítis**

**Riñón y Ojo**  
**Kidney and Eye**



**Dr. Anat Galor**

# Eye and kidney: what's the connection?

Anat Galor, MD, MSPH

Case:

- 68 y.o WM
- Presented with "**redness and ↓vision**"

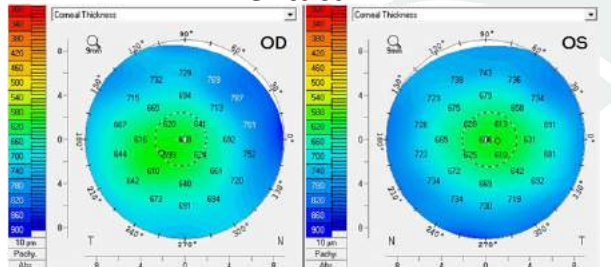
Case:

- Recently start 60 mg po prednisone for **ringing in R ear** and **acute hearing loss**
  - GERD (gastroesophageal reflux disease)
  - High cholesterol
  - Hypertension

Case:

- Va **20/200** and **20/100**
- IOP **45 mm Hg OU**
- Bulbar **conjunctival hyperemia**
- No follicles/papillae
- Bilateral **corneal edema** with bullae

## Pentacam



Case:

- Stop prednisone
- Start acyclovir
- Start IOP lower medication

When in doubt, start acyclovir

### Case:

- Edema better
- New fever
- Now see **1 + anterior chamber cells** OU
- Start prednisolone gtt

### Laboratory evaluation

- + CMV, EBV, HSV1 IgG
- Syphilis/TB negative
- C-ANCA, p-ANCA, HLA-B27 negative
- **Cr=1.7**
- **GFR=44 mL/min**
- **2+ protein on U/A**
- Protein, 24 Hour Urine 128 (<150 mg/24h)

When confused,  
order lots of  
tests

### Case:

- Turns out... had elevated Cr (1.3-1.4) for years prior to this presentation.
- Unknown cause.

### TINU??

- Typically presents with a sudden onset bilateral anterior uveitis.

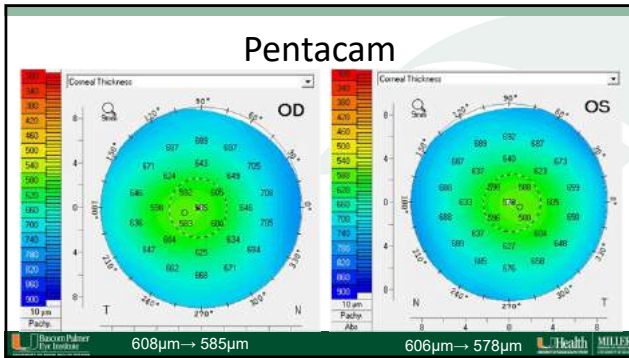
### TINU

- Epidemiology
  - Young age, ?female
- Causes
  - Drugs (anti-inflammatory, antibiotics, PPI), infections, genetic predisposition
- Histology
  - Interstitial edema, inflammatory cell infiltrates, tubular damage

Doesn't fit  
demographics or  
presentation

### TINU?

- Restart oral prednisone
- Over next month, on topical and oral corticosteroids- **corneal edema, uveitis, IOP normalized**, able to get off all drops
- **Kidney function improved** but not to normal.
- Cr=1.4, GFR 58 mL/min



### But are we correct?

- Mild **active** tubulointerstitial nephritis with eosinophils and lymphocyte

### But are we correct?

- Mild **active** tubulointerstitial nephritis with eosinophils and lymphocytes (not much edema), no GN
- Features of IgM related disorder (IgM (2+), C3 (tr), kappa light chain (tr) and lambda light chains (1+).
- Mild interstitial fibrosis (20%)– good prognostic factor.

### Why our case is atypical

- Acute bilateral anterior uveitis **simultaneous** with kidney issues.
- Here... kidney issues preceded eye inflammation by **years**?
- Renal course thought to be **independent** from ocular disease

### Take home points

- Always evaluate for **systemic disease** in individuals with uveitis.
- There is likely an **eye – kidney** connection.
  - Shared antigens?
  - Similar immune mechanisms?

## Thank you!

## Hope to see you in Miami next year!

# **Uveítis**

## **Uveítis Herpética** **Herpetic Uveitis**





**Dr. Victor L. Perez**

## Herpetic Anterior Uveitis A Treatment Challenge

XLII Inter-American Course in Clinical Ophthalmology -  
VIRTUAL EDITION

Matias Soifer, MD  
and  
Victor L. Perez, MD  
Foster Center for Ocular Immunology  
Duke Eye Center

## Case Presentation

- 31 y/o Female Patient
- 1-year story of anterior uveitis OS.
- VA: 20/30, +1 Cell, Anterior Chamber Inflammation, IOP 30
- Medical History Unremarkable, no autoimmune diseases


---

- When tapers steroids, flares again at 2 months. **Steroid Dependent.**
- Ocular Hypertension. **Steroid/Inflammation Induced Glaucoma.**
- Current Rx: Durezol 2/week, Cosopt BID







## Slit lamp Examination





- Dilated pupil
- Sectorial atrophy
- Mild AC inflammation
- High IOP
- Fundus exam: Normal
- No history of previous keratitis






## Laboratory Work Up

- **Serology:** All Negative
- **PCR Aqueous Tap:** Negative HSV1,2,HZV,CMV and EBV
- **High Parameter Flow Cytometry of Aqueous:** Immune Profile Consistent with Mixed T cell and neutrophil inflammatory response






**Dx: Herpetic Anterior Uveitis**

## Herpetic Anterior Uveitis

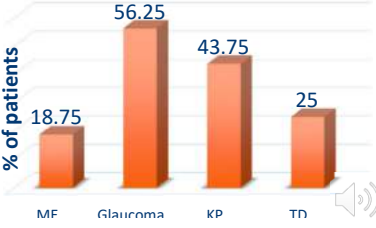
- Generally caused by HSV type 1.
- It is not clear if there is viral replication or an immune response to viral antigens.
- History Cold Sores
- Classically UNILATERAL recurrent iritis with ocular hypertension.
- Associated Iris Defects
- AC tap should be done during acute attack and test for molecular analysis (PCR) However, has low diagnostic yield.
- Herpetic Uveitis remains a CLINICAL DIAGNOSIS.



## Herpetic Anterior Uveitis

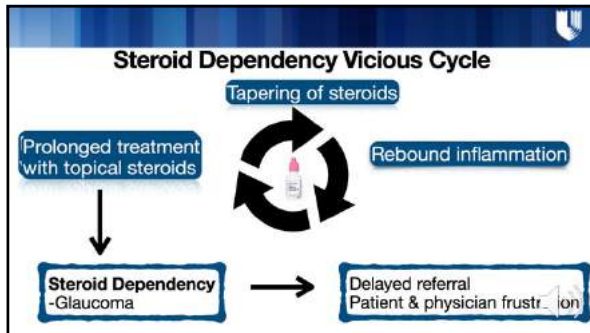
Presentation at Duke Foster Center for Ocular Immunology

- ME: Macular edema
- KP: Keratic precipitate
- TD: Transillumination Defects



Condition	% of patients
ME	18.75
Glaucoma	56.25
KP	43.75
TD	25



### Treatment Goal: NO FLARE UPS, NO STEROIDS

#### Step-Ladder Approach

- Slow Topical Steroids Tapering
- Steroid Implants
- Systemic Steroid Sparing Therapy
  - Anti-Metabolites
  - T Cells Inhibitors
  - Biologics: Anti-TNF-alpha Therapy

**BUT: THE TREATMENT OF ANTERIOR HERPETIC UVEITIS IS A CHALLENGE !**

There is an infectious component: HSV

Immune Reaction

Immune Profile Aqueous HSV Iritis

Duke Eye Center

### OUR APPROACH TO HERPETIC ANTERIOR UVEITIS

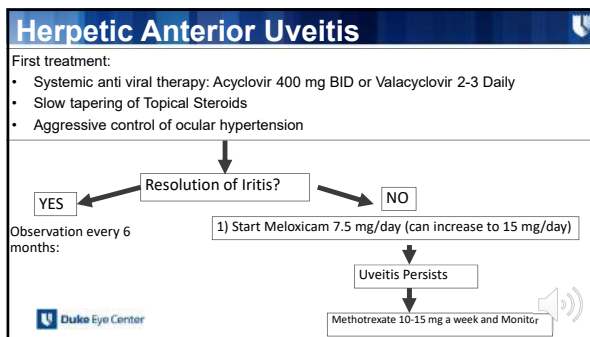
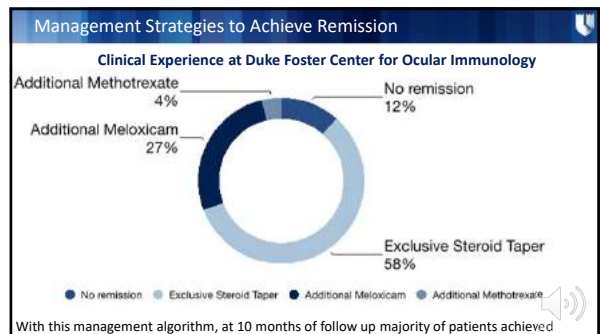
#### Step-Ladder Approach

- Systemic Antiviral Therapy: Acyclovir 400- 800 mg / day or Valtrex 1-2 gm / day
- Slow Topical Steroids Tapering
- Steroid Implants
- Aggressive IOP Control
- Systemic Steroid Sparing Therapy
  - Use of inhibitor of cyclooxygenase-2 (COX-2): Meloxicam 7.5 mg / day increase to 15 mg / day
  - Anti-Metabolites: Methotrexate mean dose 15mg once a week. Consider SC/IM route.
  - Biologics: Anti-TNF-alpha Therapy
  - T Cells Inhibitors: CSA or Tacrolimus ?

Immune Reaction

Immune Profile Aqueous HSV Iritis

Duke Eye Center

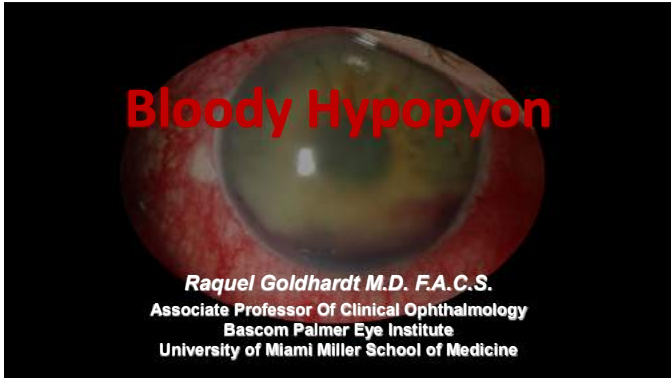


# **Uveítis**

**Hipopión Sangriento**  
**Bloody Hypopyon**



**Dr. Raquel Goldhardt**



Visual Acuity  
OS: CC 20/40  
IOP  
OS: 18 mmHg  
Pupils:  
no RAPD

OD: CF  
IOP: 26 mmHg

CAD  
s/p CABG/ICD  
Atrial fibrillation  
HTN  
Schizophrenia

ASA  
Statin  
Coreg  
Lisinopril  
Dabigatran  
Cyclobenzaprine

bascompalmer.org

**Anterior Segment Exam**

	RIGHT EYE
L/L	Normal
C/S	3+ diffuse injection
K	2+ microcystic edema no dendrite
AC	HypHEMA WBC layering inferior angle Large central fibrin collection
Iris	Poor view, round
Lens	Poor view, phakic

bascompalmer.org

**Differential Diagnosis of Hemorrhagic Hypopyon**

<b>Infectious</b> HSV VZV Tuberculosis Endophthalmitis		<b>Inflammatory</b> HLA-B27 associated Behcet's	
<b>Neoplastic</b> Leukemia Lymphoma Melanoma Retinoblastoma (less likely)		<b>Ischemic</b> NVI/NVA associated Ocular Ischemic Syndrome CRAO Vein occlusion	
<b>Other:</b> Trauma Post-surgical			

bascompalmer.org

**What to do next?**

- ~~X~~ No history of cold sores
- ~~X~~ No history of surgery
- ~~X~~ No history of cancer
- ~~X~~ No recent fevers, chills, weight loss, IV drug use
- ✓ Positive for chronic low back pain

bascompalmer.org

**What to do next?**

- Hemorrhagic hypopyon and no view posteriorly
- **High suspicion inflammatory etiology**
  - clinical history
  - extensive fibrin in AC
- We decided to treat with **topical corticosteroids while awaiting lab work and followed closely with low threshold for AC tap!**

bascompalmer.org

### RIGHT EYE

**1<sup>st</sup> ER visit**

CF OD  
IOP 26 OD  
Dx HSV ??  
Acyclovir  
Cosopt

**2 day f/u**

HM OD  
IOP 23 OD  
**Start PF Q1h, cyclogyl**  
Continue acyclovir  
Continue cosopt

**4 day f/u**

CF 6' OD  
IOP 10 OD  
PF Q1h, cyclogyl  
Continue acyclovir  
Continue cosopt

GLOBAL CENTER FOR COMPLEX EYE DISEASES  
sascompalmer.org

### HLA-B27 - Positive

**1 week**

20/100  
IOP 6 mmHg  
PF Q1h  
Cyclogyl  
STOP acyclovir/cosopt

**2 weeks**

20/40  
IOP 10 mmHg  
Trace - 1+ cells  
PF Q2h  
Cyclogyl

**6 weeks**

20/30  
IOP 10 mmHg  
Trace cells  
PF 6 times/day  
Cyclogyl

GLOBAL CENTER FOR COMPLEX EYE DISEASES  
sascompalmer.org

### Further Work-up

**10 weeks**

20/30 OD  
IOP 13 OD  
PF taper  
Stop cyclogyl

**14 weeks**

20/20 OD  
IOP 8 OD  
PF taper

GLOBAL CENTER FOR COMPLEX EYE DISEASES  
sascompalmer.org

### HLA-B27-associated anterior uveitis ankylosing spondylitis

#### Complications of HLA-B27-Associated Uveitis

- Posterior synechiae (13-90%)
- Cataract formation (7-28%)
- Ocular hypertension
- Cystoid macular edema
- Optic nerve edema
- Epiretinal membrane
- Band keratopathy

**Most common**

GLOBAL CENTER FOR COMPLEX EYE DISEASES  
sascompalmer.org

### Take Home Points

**Hemorrhagic hypopyon:**  
-rare presentation of acute anterior uveitis  
-thorough history to rule out other pathology

Be aware: **HLA-B27 uveitis complications**  
obtain appropriate imaging

Test for HLA B27  
Chronic lower back pain  
Plantar heel pain

**Rule out infectious causes in ALL patients**

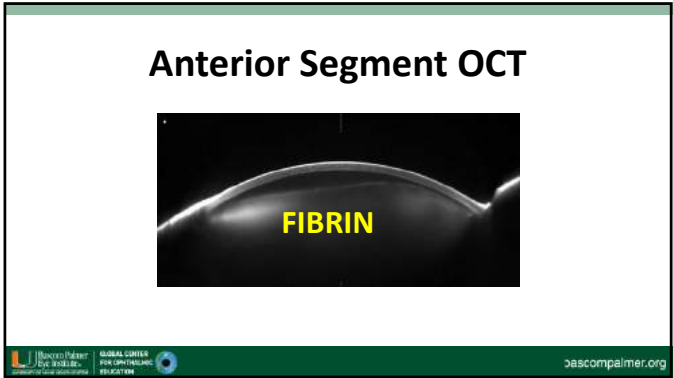
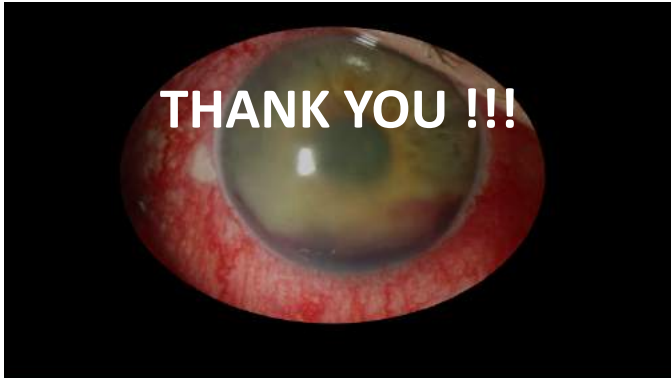**Important to work closely with rheumatology colleagues for proper diagnosis and management of underlying systemic illness**

GLOBAL CENTER FOR COMPLEX EYE DISEASES  
sascompalmer.org

### Treatment - Take Home Points

- Depends on the severity and location of inflammation**
- \*First line topical corticosteroids (extend for at least 8 weeks) and cycloplegics
- If severe inflammation or posterior involvement**
  - Oral corticosteroids
  - Periocular and intravitreal corticosteroid injections **RULE OUT INFECTION!!!**
- DMARDs NOT effective if purely axial spondyloarthritis**
  - known efficacy in the treatment of uveitis and reduces relapses
- TNF inhibitors effective in treatment of axial spondyloarthritis**
- Carries significant infectious risk
  - What is the role in uveitis? **Adalimumab: reduces anterior uveitis flares**

GLOBAL CENTER FOR COMPLEX EYE DISEASES  
sascompalmer.org



### Back to Hemorrhagic Hypopyon

- **Hypopyon** is uncommon in uveitis
  - risk factors: Behcet's, spondyloarthritis, HLA-B27
  - Zaidi et al report hypopyon in 6% of patients with HLA-B27 associated uveitis

Zaidi AA, Ying GS, Daniel E, Gargaputra S, Rosenbaum JT, Schler EB, et al. Hypopyon in patients with uveitis. *Ophthalmology*. 2010;117:366-72. doi: 10.1016/j.ophtha.2009.07.025

ONH and RNFL OU Analysis: Optic Disc Cube 200x200 OD OS

Average RNFL Thickness	122 µm	94 µm
RNFL Systemic		
Disc Area	1.93 mm <sup>2</sup>	1.24 mm <sup>2</sup>
Average CD Ratio	0.08	0.09
Vertical CD Ratio	0.06	0.07
Cup Volume	0.094 mm <sup>3</sup>	0.022 mm <sup>3</sup>

### Treatment of Axial Spondyloarthritis

- First line non-pharmacologic or NSAIDs
- DMARDs (ie methotrexate, azathioprine) **NOT effective for the arthritic manifestations of purely axial spondyloarthritis**
  - known efficacy in the treatment of uveitis
- **TNF inhibitors effective in treatment of axial SpA**
  - Carries significant infectious risk
  - What is the role in uveitis?

Al-Calhoft J et al. Efficacy of TNF-blockers in patients with ankylosing spondylitis and non-radiographic axial spondyloarthritis: a meta-analysis. *Ann Rheum Dis*. 2015;74(4):1241. Epub 2014 Apr 9.

# **Uveítis**

**Edema Macular Cistoide Recalcitrante**  
**Recalcitrant Cystoid Macular Edema**



**Dr. Janet L. Davis**

# Recalcitrant CME

Janet Davis MD  
Professor of Ophthalmology  
Bascom Palmer Eye Institute  
No financial disclosures relevant to the presentation



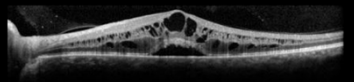
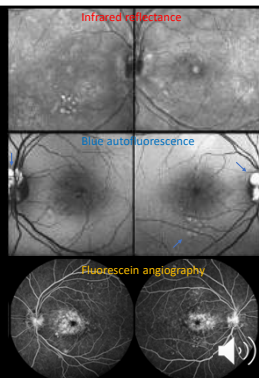
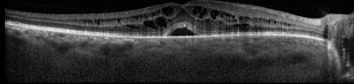
## CME without apparent cause

- 65 years old man
  - Ocular hypertension for 10 years, treated with bimatoprost
  - Decreased vision for several months - phakic
    - 20/30 right eye      20/50 left eye
    - IOP 21 right eye      IOP 17 left eye
  - +1.75 hyperopia
  - No iritis
  - Optic nerve head drusen
  - Colloid macular drusen



## Initial examination

• 8/2018



## Additional medical history

### Lymphadenopathy

- Abnormal Kappa/Lambda ratio
- Free light chain present
- No monoclonal band
- Biopsy negative

### Autoimmune panel negative



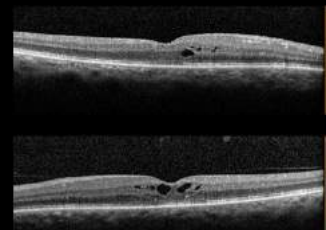
## Initial treatment Shotgun 8/9/2018

- Stop **bimatoprost** (prostaglandin analogue)
- Start **brinzolamide** (topical carbonic anhydrase inhibitor)
- Start **difluprednate** drops TID (topical corticosteroid)
- Start **ketorolac** drops TID (topical non-steroidal anti-inflammatory)



## Response to initial treatment 10/22/2018

- OCT: complete resolution of SRF, improved IRF
- IOP 32 and 30
- **Difluprednate** reduced to BID
- **Ketorolac** continued TID
- Change brinzolamide to **dorzolamide-timolol**



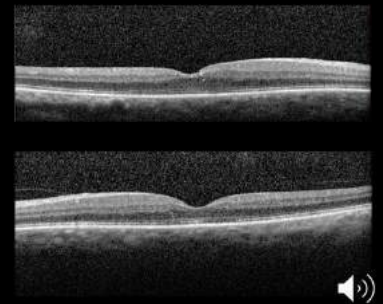
## Treatment adjustment 11/15/2018

- 20/30 and 20/40
- 21 and 20
- Continue dorzolamide-timolol BID OU
- Add brimonidine BID OU
- Reduce ketorolac to BID OU
- Reduce difluprednate to daily OS, continue BID OD



1/31/2019

- 20/30 and 20/40
- IOP 35 and 37
- Difluprednate stopped
- Latanoprost started
- Dorzolamide-timolol and brimonidine continued
- Ketorolac continued BID




## Follow-up

5/18/2019

- Latanoprost continued
- Dorzolamide stopped
- Timolol started
- Ketorolac BID continued

9/10/2019

- Latanoprost nightly
- Timolol daily
- Ketorolac daily

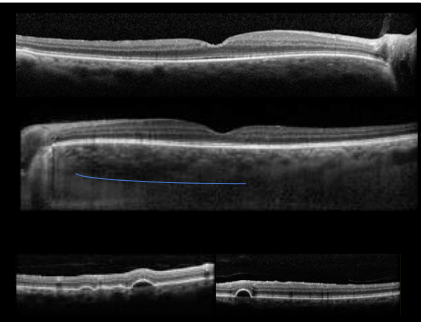


Stable glaucoma confirmed by outside VF and RNFL from 2016



12/19/2019

- 20/20 and 20/25
- Stopped ketorolac
- Plano
- Hyperopia resolved
- IOP 15 and 12
- Latanoprost
- Timolol



Pigment epithelial detachments and colloid drusen both eyes



## Non-uveitic, non-diabetic, non-CRVO CME

### Exotic causes

- Drugs: prostaglandin analogues
- Blood flow: free light chains
- Anatomic
  - Optic nerve drusen
  - Thick choroid

### Standard treatments

- Topical corticosteroids
  - Reduced vascular leakage
  - Increased IOP
- Non-steroid anti-inflammatory
- Carbonic anhydrase inhibitors

Recalcitrant, no, recurrent, probably



# **Uveítis**

**Más Riñones**  
More Kidney



**Dr. Thomas A. Albini**




Disclosures

- None

**Presentation**

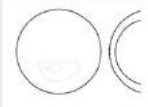
- 52-year-old female with hypertension and DM
- Blurry vision, pain, redness and lid swelling in her left eye that started after flu like symptoms and outer lip sore for 11 days prior
- Diagnosed with chorioretinitis and prescribed prednisolone and atropine drops three days prior
- No prior ocular surgery or trauma
- No history of autoimmune disease, joint pain, fever, rash, recent travel, recent hospitalization, immunosuppressive therapy, sick contacts, intravenous drug use, tuberculosis, and sexually transmitted diseases



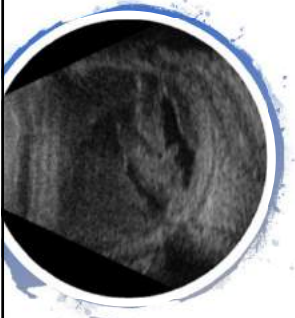
**Presentation**

VA 20/20 OD  
CF OS  
IOP 15 OD  
STP OS

Slit Lamp Exam	Right	Left
Lids/lashes	Normal	significant upper lid edema
Conjunctiva/sclera	White and quiet	4+ chemosis and injection folding over on the cornea
Cornea	Clear	hazy, edema
Anterior Chamber	Deep and quiet	likely large isoaque fibrin clot. Mem hyalogen at 3 o'clock. AC appears formed
Iris	Round and flat	appears flat, hazy view
Lens	trusc	no view



**B-Scan OS**



- The vitreous is filled with dense, non-mobile vitreous opacities and membrane formation, some of them inserting posteriorly in the optic disc area. Cannot rule out retinal detachment in the setting of endophthalmitis.
- Grossly, no mass lesion detected.
- Diffuse fundus thickening with 360 degree Tenon's infiltration from anterior to the equator to posterior to the equator.

**Laboratory Work-up**

- Leukocytosis
- Thrombocytosis
- Positive HSV IgG
- Negative infectious work up including toxoplasmosis IgM and IgG, HSV IgM, RPR, Quantiferon gold, and anterior chamber cultures negative for growth.

## Treatment

- AC tap for cultures, gram stain and PCR
- Intracameral vancomycin and ceftazidime

## Treatment

- - Start Valtrex 2g TID PO
- - Start prednisone 60mg PO
- - Start bactrim DS BID PO
- - Start Polytrim QID OS
- - Start PF q1h OS
- - Start Atropine BID OS
- - Strict return precautions discussed

## Diagnostic Vitrectomy One Month Later

- PPV with Silicon Oil Infusion
- Clinical Impressions possible fungal endophthalmitis – intravitreal voriconazole given
- Cultures: moderate growth of pansensitive *Citrobacter koseri*
- Intravitreal ceftazidime and vancomycin
- ID consult
- Oral levofloxacin and metronidazole

## *Citrobacter koseri*

- Gram-negative, non-spore-forming bacillus. It is a facultative anaerobe capable of aerobic respiration
- Majority of isolates from urinary tract infections
- Third most common organisms causing UTI in hospitalized patients after *Escherichia coli* and *Klebsiella* species accounting for 9.4% of all isolates
- *Citrobacter diversus* has been found to be an important cause of neonatal meningitis and brain abscesses

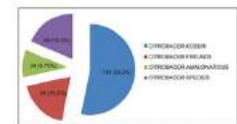


Figure 1: prevalence of different *Citrobacter* spp. isolates

Sami H, Sultan A, Rizvi M, Khan F, Ahmad S, Shukla I, et al. *Citrobacter* as a uropathogen, its prevalence and antibiotics susceptibility pattern. *CHRISMED J Health Res* 2017;4:23-6.

## CITROBACTER ENDOGENOUS ENDOPHTHALMITIS: A CASE REPORT AND REVIEW OF THE LITERATURE

Daniel H. T. Wong, MRCS,\*† Candice C. H. Liu, MRCS,\*† Justin M. K. Tong, FRCS,\*† Wei-Kwang Luk, FRCPA,‡ Kenneth K. W. Li, FRCS, FRCOphth,\*†

**Purpose:** We present a case of endogenous endophthalmitis because of an unusual bacterium, *Citrobacter koseri*.

**Patient:** A 55-year-old woman without previous history of eye surgery or trauma presented with diabetic retinopathy and a painful right eye with the reduction of vision. *C. koseri* was identified in blood culture. Thus, a diagnosis of right eye endogenous endophthalmitis was made. Intravenous and intravitreal antibiotics were both started, and vitreous culture further confirmed *C. koseri* as the causative organism. Continued management of the diabetes and patient received a right C3-injected perinephric abscess, which was drained under ultrasonographic guidance.

**Results:** Because of rapid progression to vitreal melting, enucleation was performed.

**Conclusions:** Cases of endogenous endophthalmitis caused by *Citrobacter* are very limited, and a review of all published cases in the English literature and the present case revealed that endogenous *Citrobacter* endophthalmitis arose almost entirely from *Citrobacter* renal infections. Early recognition and drainage of renal abscess may lower the chance of uncontrolled infection and endogenous spread to the eyes. Despite prompt and intensive treatment, the critical outcome of *Citrobacter* endogenous endophthalmitis

Wong DHT, Liu CCH, Tong JMK, Luk WK, Li KKW. CITROBACTER ENDOGENOUS ENDOPHTHALMITIS: A CASE REPORT AND REVIEW OF THE LITERATURE. *Retin Cases Brief Rep.* 2020 Spring;5(2):187-191.


## Back to our patient

- The CT scan of the abdomen and pelvis did not demonstrate renal or perinephric abscess but did show a 1.1cm non-obstructing renal stone in the right renal pelvis.
- MRI of the abdomen and pelvis revealed an abnormal appearance of the right kidney with areas of restricted diffusion in a striated pattern suggestive of chronic pyelonephritis; there was no apparent fluid collection.
- Treated by ID with a course of metronidazole.
- Eye became NLP and phthisical.

Thanks!

---

- Marissa M. Patel, BA
- Lily Zhang, MD
- Sulaiman Alhumaid, MD
- Jonathan F. Russell MD, PhD



# **Oncología** **Oncology**

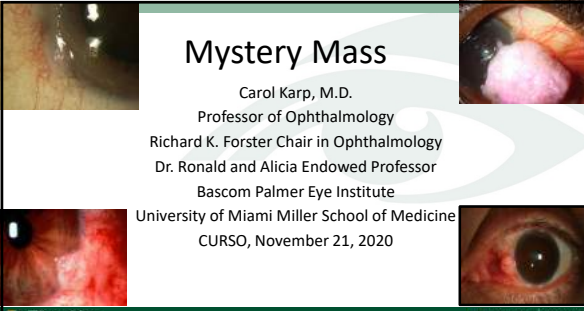


**La Masa Misteriosa**  
**Mystery Mass**



**Dr. Carol L. Karp**

# Mystery Mass

Carol Karp, M.D.  
 Professor of Ophthalmology  
 Richard K. Forster Chair in Ophthalmology  
 Dr. Ronald and Alicia Endowed Professor  
 Bascom Palmer Eye Institute  
 University of Miami Miller School of Medicine  
 CURSO, November 21, 2020

# DISCLOSURES

- I have no financial interests to disclose
- I will be discussing off label use of FDA approved drugs
- Special thanks to Dr. Despoina Theotoka, Dr. Michael Zein, and Sarah Wall for the help with the case presentation
- Thanks to my research team: Dr. Anat Galor, Dr. Despoina Theotoka, Sarah Wall, Dr. Ghada Al Bayyat, Dr. Dan Arreaza, Dr. Melina Morkin, Dr. Carolina Mercado, Osmel Alvarez, Dr. Sander Dubovy, Dr. Ibrahim Osama, Dr. Swarup Swaminathan, Dr. Nandini Venkataswaran, Dr. Asaf Friehtmann, Dr. Ann Tran, Dr. Rebecca Tanenbaum, Dr. Madhura Joag, Dr. Marwan Atallah, Dr. Guillermo Amescua, Dr. Afshan Nanji, Dr. Jeremy Kievall, Dr. Adam Sise, Dr. Juan C. Murillo, Dr. Sander Dubovy, Dr. Mohamed Abou Shousha, Dr. Antonio Bermudez, Dr. Christina Moon, Dr. Michael Tsatsos, Dr. Adam Sise, Dr. Jeremy Kievall, Dr. Leila Vejovic, Dr. Jane Fishler, Dr. Hatim Batawi, Dr. James Wong, Dr. Sotiria Palioura, Dr. Nabeel Shalabi, Dr. Juan Battle, Dr. Fouad El Sayyad, Dr. Ben Thomas, Dr. Patrick Oellers, Dr. Fasika Woreta, Dr. Bill Harbour, Dr. Zelia Correa, Dr. Victor Perez, Dr. Jesus Davila, Dr. Maria Romero




# CC: "This mushroom is growing from my eye over the last month"

- Mass on left eye
- H/o HIV infection
- H/o of retinal detachment and scleral buckle 37 years ago






<https://nature.mdc.mg.gov/discover-nature/field-guide/emetic-russula>



# CC: "This mushroom is growing from my eye over the last month"

- Papillomatous
- Mobile
- Stains with lissamine







<https://nature.mdc.mg.gov/discover-nature/field-guide/emetic-russula>



# CC: "This mushroom is growing from my eye over the last month"

- Papillomatous
- Mobile
- Stains with lissamine






<https://nature.mdc.mg.gov/discover-nature/field-guide/emetic-russula>





# Differential diagnosis

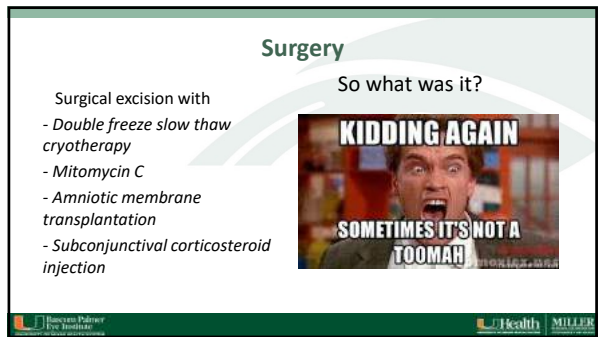
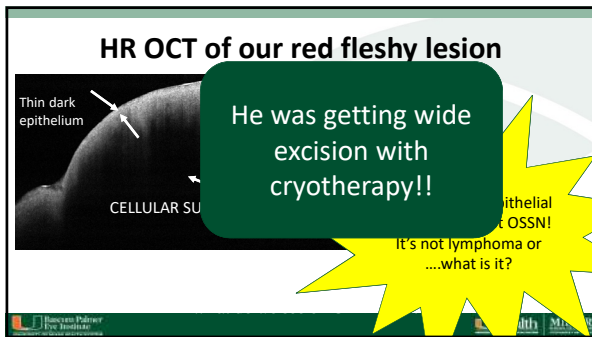
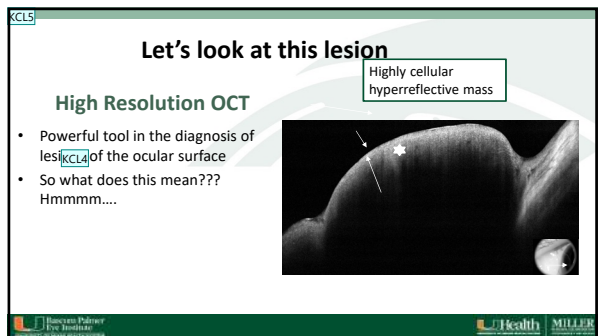
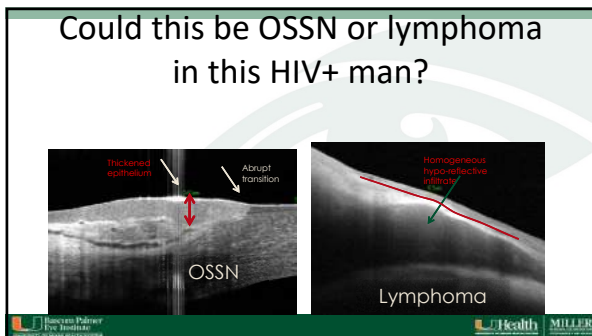
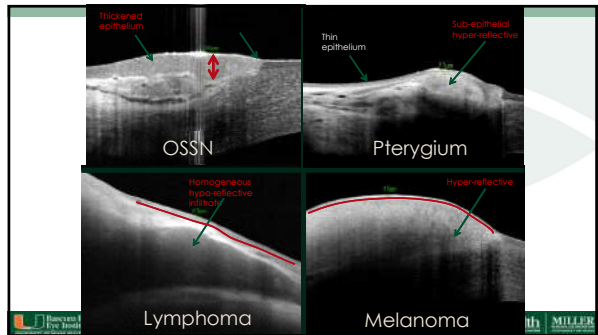
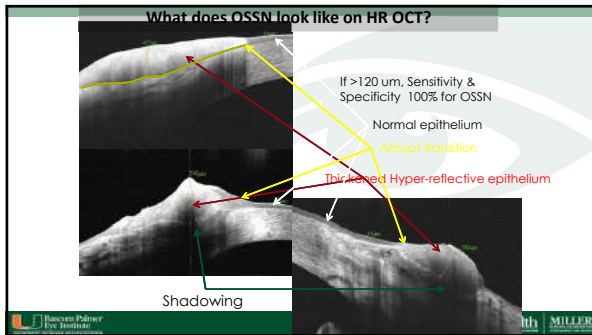
- OSSN
- Lymphoma
- Papilloma
- Pyogenic granuloma
- Some kind of mushroom?



What Mushroom are you?  
Original Mushie


Gif credit: www.giphy.com



### Surgery plan:

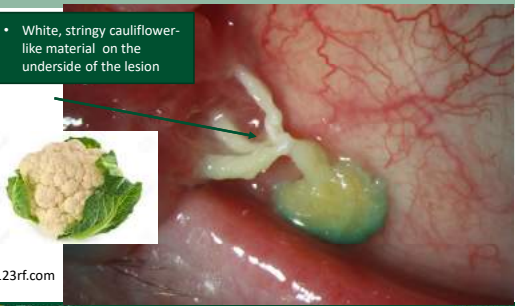
- Double freeze slow thaw cryotherapy
- Mitomycin C
- Amniotic membrane transplantation
- Subconjunctival corticosteroid injection



HERE IS WHAT I SAW.....

Barbara Palmer Eye Institute | Health MILLER

- White, stringy cauliflower-like material on the underside of the lesion



123rf.com

Barbara Palmer Eye Institute | Health MILLER

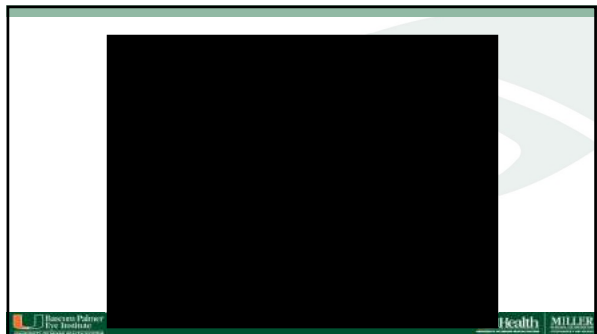


WHY STRAWTY WHY? YOU COMPARE ME TO THAT? WHAT HAVE I EVER DONE TO YOU?


Are these ingredients for a great salad? Is this a TOOMAH?

Plantbasedcooking.com

Barbara Palmer Eye Institute | Health MILLER



### Pathology



Pyogenic granuloma/  
SILK SUTURE GRANULOMA  
from his surgery 37 years  
prior!

Courtesy of Dr. Sander Dubovy

Barbara Palmer Eye Institute | Health MILLER

### Other reported cases

- [Silk Suture Granuloma After High Orchiectomy]
- An Exceptional Case of Suture Granuloma 30 Years Following an Open Repair of Achilles Tendon Rupture: A Case Report
- Rare Complication of Varicose Veins
- Symptomatic Suture Granuloma
- Silk Suture Appendectomy
- Silk Suture Granuloma With False-Positive Findings on PET/CT Accompanied by Peritoneal Metastasis After Colon Cancer Surgery

Formation of pyogenic granuloma can range from weeks to years ..

Barbara Palmer Eye Institute | Health MILLER

**Pyogenic granuloma usually is soon after surgery, but not always....**

**Silk Suture Granuloma After High Orchiectomy]** Suture Granuloma Showing False-Positive Findings on FDG-PET

**Rare Complication**

**Nuestro caso es la presentación mas tardía de un granuloma piogénico en la literature actual!!**

**After picking the mushroom Post op...the eye looks great...**

**Conclusion**

- This was the most delayed pyogenic granuloma ever reported in the literature, 37 years later!
- Think pyogenic granuloma even if years after a surgery, especially if non-absorbable suture used.
- HR OCT is very helpful adjunct in the management of ocular surface tumors.

**Thank you!**

It was NOT A MALIGNANT TUMOR!  
A silk suture granuloma 37 years post op!!!

# **Oncología**

# **Oncology**

**Ascendencia Genética en Oncología Ocular**  
**Genetic Ancestry in Ocular Oncology**




**Dr. J. William Harbour**





**XLII Curso Interamericano del Bascom Palmer – EDICIÓN VIRTUAL**




## Genetic ancestry in ocular oncology






**J. William Harbour, MD**  
 Professor & Vice Chair  
 Bascom Palmer Eye Institute  
 Sylvester Comprehensive Cancer Center  
 University of Miami School of Medicine




### What is genetic ancestry?

- It is NOT self reported ethnicity or race
- It is NOT family history
- It is a quantitative method for inferring the genetic composition of an individual from well-defined ancestral groups (e.g., European, Asian, African, Native American)
- Overall (global) ancestral admixture and the inheritance of specific (local) chromosomal segments can be determine




### Why is genetic ancestry useful in medicine?

- Some determinants of disease susceptibility and severity are inherited from defined ancestral groups







### Importance of genetically admixed individuals

- Genomic characterization of admixed human populations enables the deconvolution of complex traits such as glaucoma and cancer
- What part of disease susceptibility and severity are genetic versus environmental/socioeconomic?
- Latin America represents one of the most genetically diverse population in the world



### What role does genetic ancestry play in ocular oncology?

**Impact of Genetic Ancestry on Prognostic Biomarkers in Uveal Melanoma**

Daniel A. Rodriguez<sup>1,2,5</sup>, Margaret I. Sanchez<sup>1,2,3</sup>, Christina L. Decatur<sup>1,2,3,4</sup>, Zelia M. Correa<sup>1,2,3,4</sup>, Eden R. Martin<sup>4,5</sup> and J. William Harbour<sup>1,2,3,4</sup>

Published October 31, 2020

### Genetic ancestry in uveal melanoma

- We created a bioinformatic pipeline and assembled 1381 control individuals from West African, European, East Asian, as well as 49 Native American populations

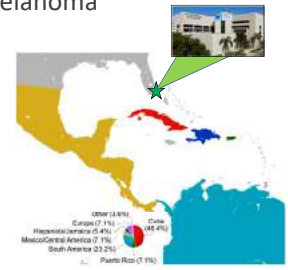Ancestral Group	Subpopulation
European	British, Italian, Toscani, Finnish, Utahresidents
West African	GambianMandinka, Mende, Esan, Yoruba, Luhya
East Asian	Han Chinese, Han Chinese, Japanese, Southern Han Chinese, Kinh Vietnamese
Native American	Alouari, Algerian, Anzai, Ashoson, Ayman, Bihari, Cabecar, Chiric, Chibche, Chipewyan, Chiric, Chontalpa, Cree, Dugway, Edebi, Ewe, Gwari, Guaymá, Huarpe, Huli, Inga, Jaramana, Kanggari, Kapishiki, Karitona, Kogi, Maloku, Maya, Miao, Miskito, Ojibwa, Palikur, Panakota, Papioco, Pano, Purupucha, Quechua, Senu, Tordjbanoo, Tsimbe, Tsimbe, Tsimbe, Wozumna, Wayana, Wollmat, Wichita, Yaghan, Yaguai, Zapotec



Rodriguez ... Harbour, Cancers (20, 0)

### Genetic ancestry in uveal melanoma

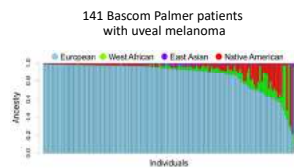
- A bioinformatic pipeline was assembled using 1381 control individuals from West African, European, East Asian, as well as 49 Native American populations
- An initial pilot study was performed in 141 uveal melanoma patients from Bascom Palmer



Rodriguez ... Harbour, Cancers (20, 0)

### Genetic ancestry in uveal melanoma


- Genetically diverse patient population at Bascom Palmer
- Uveal melanoma not only a cancer of white Europeans



Rodriguez ... Harbour, Cancers (20, 0)

### Genetic ancestry in uveal melanoma

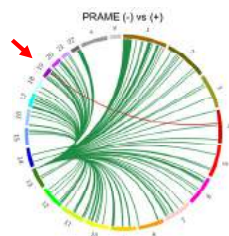
- Genetically diverse patient population at Bascom Palmer
- Uveal melanoma not only a cancer of white Europeans



Rodriguez ... Harbour, Cancers (20, 0)

### Genetic ancestry in uveal melanoma

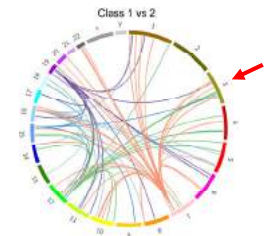
- High risk PRAME expression profile associated with increased proportion of European background



Rodriguez ... Harbour, Cancers (20, 0)

### Genetic ancestry in uveal melanoma

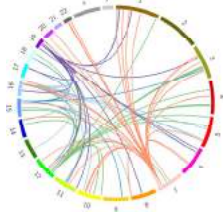
- High risk class 2 gene expression profile associated with immune genes on chromosome 3 (near the COVID-19 Neanderthal gene cluster)



Rodriguez ... Harbour, Cancers (20, 0)

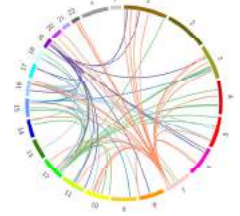
## Genetic ancestry in ocular oncology

- Ancestry plays a role in disease susceptibility and severity
- Latin American populations are among those most affected by differences in genetic ancestry



## Genetic ancestry in ocular oncology

- International collaborations are needed
  - Uveal melanoma
  - Retinoblastoma
  - Other ocular tumors
  - Other ophthalmic conditions



A photograph of two individuals, a man and a woman, standing in front of the Bascom Palmer Eye Institute building. The man is wearing a grey polo shirt and glasses, and the woman is wearing a grey polo shirt. The building has a sign that reads 'Bascom Palmer Eye Institute' and another sign that says 'Ranked #1 in the USA'.



[harbour@med.miami.edu](mailto:harbour@med.miami.edu)

[zcorrea@med.miami.edu](mailto:zcorrea@med.miami.edu)

Drs. William Harbour & Zelia Correa

Bascom Palmer  
Eye Institute



# **Oncología**

# **Oncology**

**Manejo Complejo del Melanoma Coroideo**  
**Complex Management of Choroidal Melanoma**



**Dr. Zelia M. Correa**

## Complex management of choroidal melanoma

Zélia M Corrêa, MD, PhD

*Professor of Ophthalmology  
Co-Director Ocular Oncology Program  
Bascom Palmer Eye Institute  
University of Miami Miller School of Medicine*



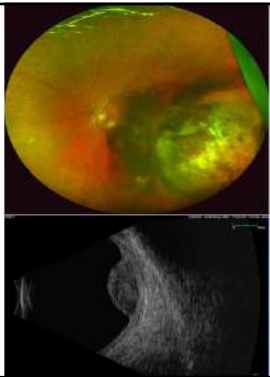
Financial disclosure

Consultant for Castle Biosciences, Inc



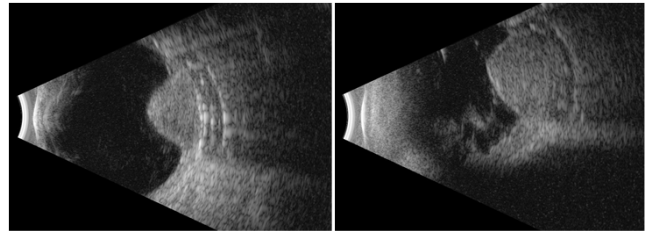
### Case presentation

- 82 year-old man with progressive vision loss OS
  - BCVA OD – 20/25 OS – LP
  - IOP within normal limits
  - Age related cataract OU
- PMHx
  - Hypertension
  - CAD (taking Plavix)
  - hypercholesterolemia



Plaque insertion

Plaque removal



### DecisionDx-UM Result

**Class 1B**

Discriminant Value: 1.06

Class 1 molecular signature is associated with a low risk of near term (within 5 years) clinical metastasis. Subanalysis indicates a Class 1B tumor which carries a higher metastatic risk than other Class 1 tumors. A discriminant value  $\geq 0.100$  is reported with normal confidence.

Test Results should be interpreted using the Clinical Experience information contained in this report which is derived from clinical studies involving patients with specific clinical features as noted in section titled Clinical Experience. These results have not been validated in patients with clinical features different from those described. This discriminant value relates to Class 1 vs 2. See page 2 of report for discussion on discriminant value confidence.

### DecisionDx-PRAME Result

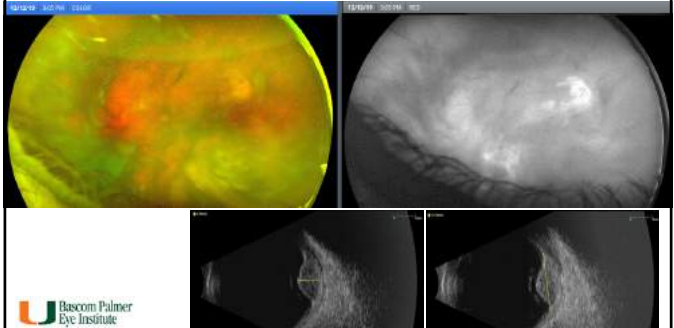
**PRAME positive**

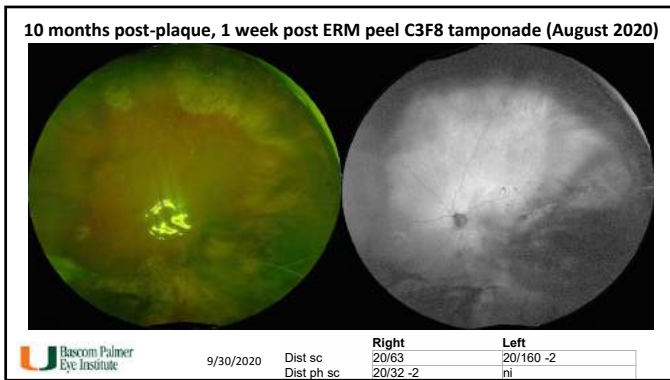
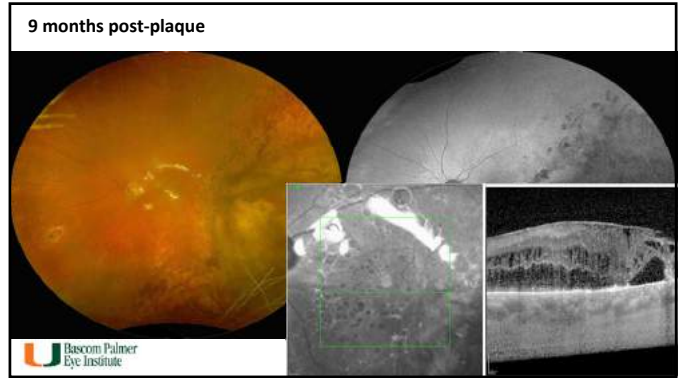
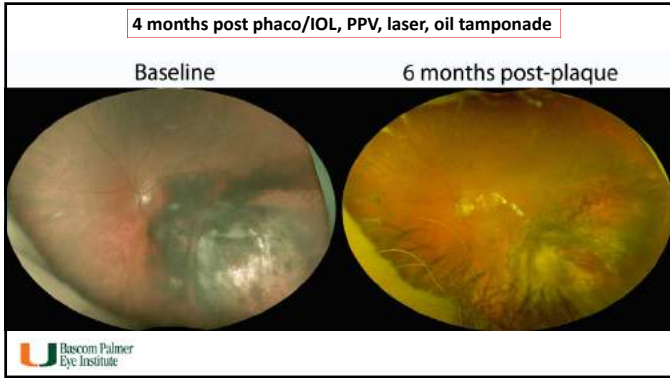
PRAME positivity has been reported to be associated with an increased risk of metastasis in patients with Class 1 uveal melanoma and shorter time to metastasis in patients with Class 2 uveal melanoma.

The role of PRAME status in the risk of metastasis of uveal melanoma has been reported in retrospective datasets<sup>1,2</sup> and these findings are the subject of ongoing clinical research studies.



### 2 months post-plaque






Take home message

- Conservative management of choroidal melanoma has become a complex, multi-step process
- Considering patient's needs and prognosis is important
- Open communication and patient buy-in is essential

Bascom Palmer Eye Institute



# **Oncología**

# **Oncology**


**El Asunto es el Tejido**  
**Tissue is the Issue**



**Dr. Sander R. Dubovy**

## When the Tissue is the Issue

XLII Inter-American Course in Clinical Ophthalmology-Virtual Edition




Sander R. Dubovy, MD  
 Professor of Ophthalmology and Pathology  
 Victor T. Curtin Chair in Ophthalmology  
 Florida Lions Ocular Pathology Laboratory  
 Bascom Palmer Eye Institute  
 University of Miami Miller School of Medicine

bascompalmer.org

## No relevant financial disclosures

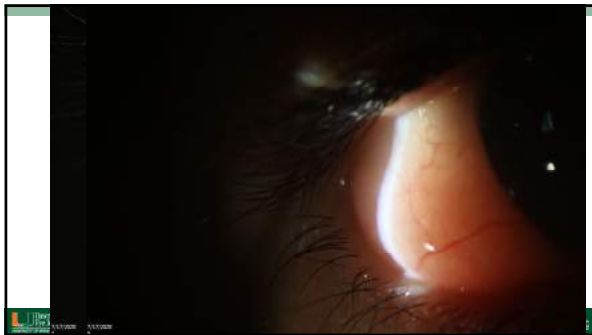
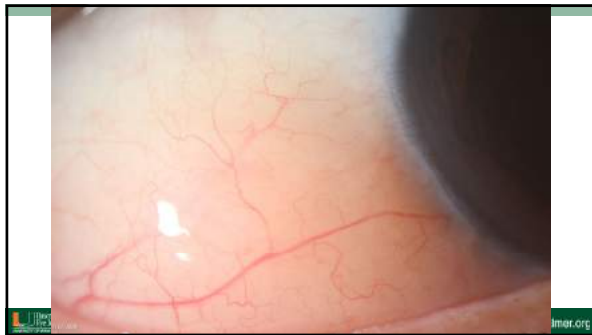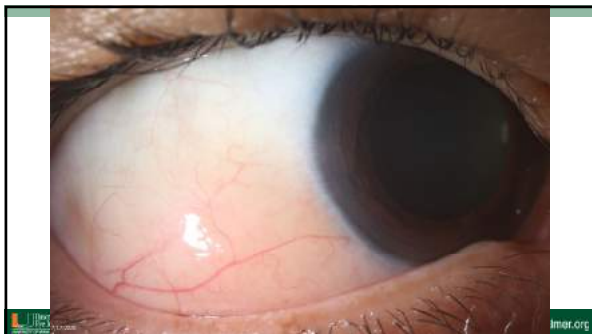
bascompalmer.org

### 50 year old female






- Referred for conjunctival lesion x 3 years with growth
- PMH: Breast cancer in remission
- POH: Laser surgery

bascompalmer.org






**WHAT COULD THIS BE?**

- Lymphoma
- Reactive lymphoid proliferation
- Amelanotic melanoma
- Amyloid
- Histiocytosis
- Fat prolapse
- Sarcoid or other granulomatous process

**WHAT TO DO?**

**Diagnosis of Ocular Surface Lesions Using Ultra-High-Resolution Optical Coherence Tomography**




Journal of Ocular Biology and Disease | Volume 2018 | Issue 1 | Page 1-11

Eye and Vision

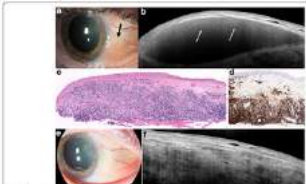
**RESEARCH** Open Access




The use of high resolution anterior segment optical coherence tomography for the characterization of conjunctival lymphoma, conjunctival amyloidosis and benign reactive lymphoid hyperplasia

Randee Venkatesan<sup>1</sup>, Carolina Alencar<sup>2</sup>, Aron G. Tsai<sup>3</sup>, Anandhi Gopal<sup>4</sup>, Pedro Henrique Mouton Star<sup>5</sup>, Sarah R. Dubey<sup>6</sup>, Anil Gopal<sup>7</sup> and Carl L. Karp<sup>8</sup>









• Lymphoma



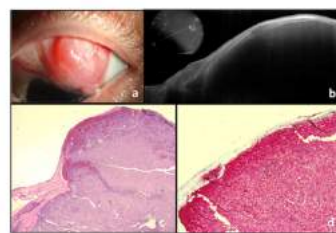







• Reactive Lymphoid



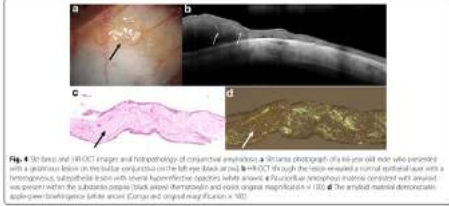




• Melanoma



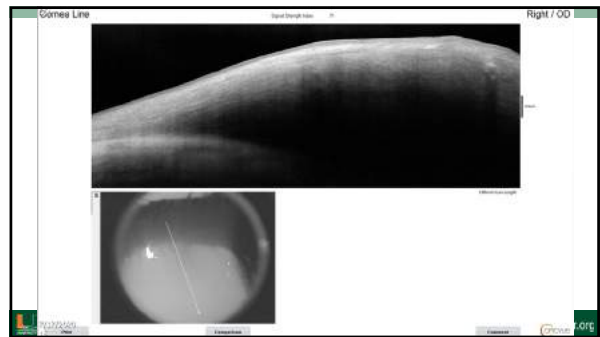
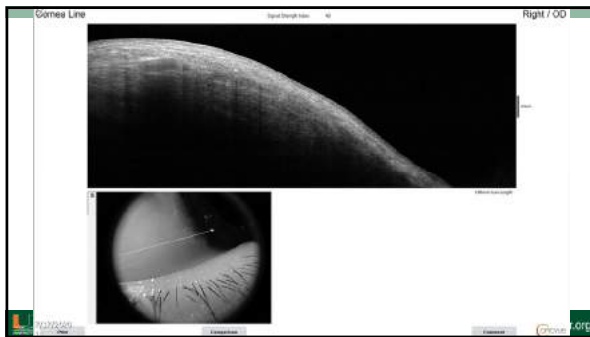
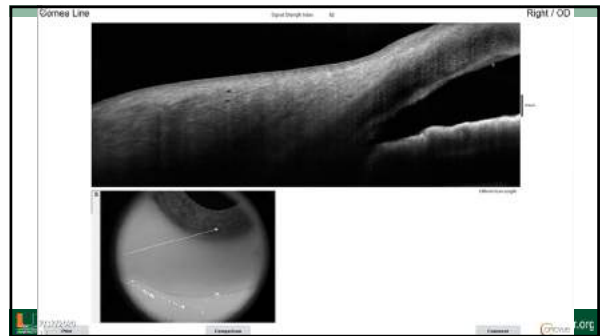
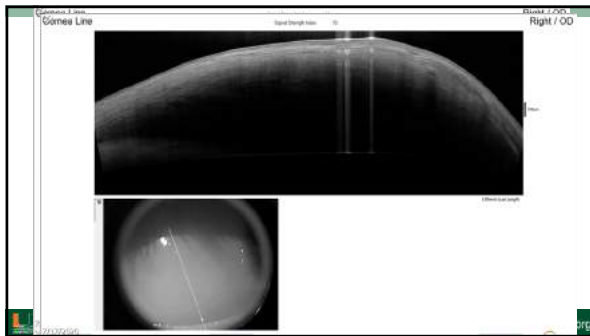




- Amyloid



**Fig. 4** 3D scans and histology of conjunctival amyloidosis. **a** 3D scan photograph of the eye with a green line on the bulbar conjunctiva on the left eye. **b** 3D scan photograph of the biopsy site. **c** Histology of the biopsy revealed a normal conjunctival epithelium with a lamellated, subepithelial lesion with sparse hyaline eosinophilic granules within vessels. **d** The conjunctival amyloid material stained positive with amyloid as present within the sublamellar lamellae (black arrow). Hematoxylin and eosin original magnification  $\times 100$ . **e** The amyloid material demonstrated apple-green birefringence (white arrow). Congo red original magnification  $\times 100$ .

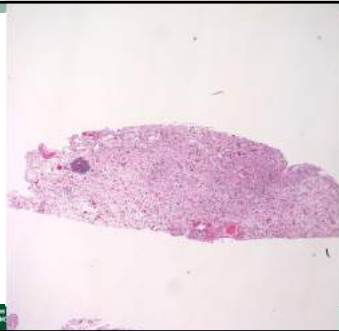
## OUR CASE



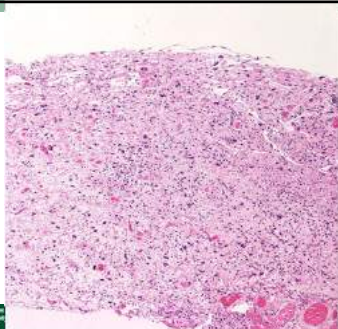
# Histopathology

Tissue is the Issue

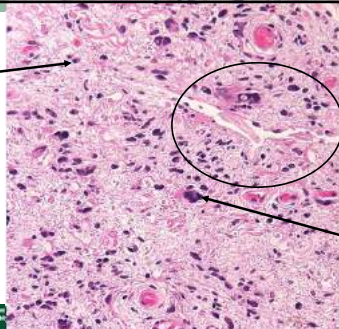
Hematoxylin and eosin,  
original magnification x  
40



Hematoxylin and eosin,  
original magnification x  
100

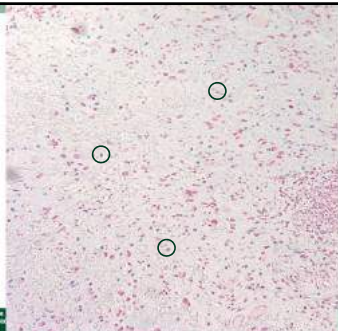


Hematoxylin and eosin,  
original magnification x  
400

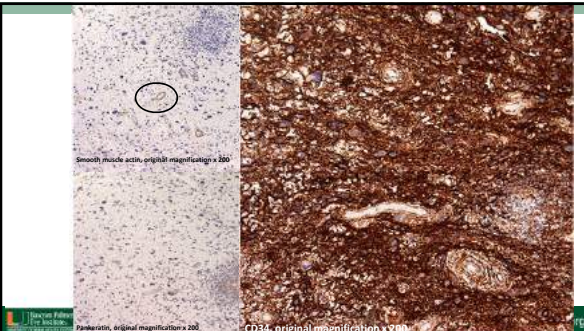


Mast cells with Alcian  
blue positivity

Alcian blue, original  
magnification x 200

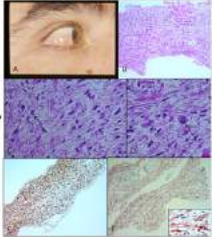


Smooth muscle actin, original magnification x 200



### Conjunctival Stromal Tumor: Report of 4 Cases


Heaven C. Hirng, MD,<sup>1</sup> Jai G. Shah, MD,<sup>2</sup> Marc C. Greenlee, MD, MS<sup>1</sup>



*Ophthalmology* 2012;119:682-

bascompalmer.org

### Conjunctival Stromal Tumor



- Bulbar conjunctiva age 41-53
- None developed recurrence after excisional biopsy
- All had spindle shaped cells with pseudonuclear inclusions
- Stroma myxoid to collagenous
- Reactive/inflammatory component needs to be considered in the pathogenesis of the lesion

bascompalmer.org

<h4>Myxoma</h4> <ul style="list-style-type: none"> <li>• CD34 (-)</li> <li>• S100 +</li> <li>• Smooth Muscle (+)</li> <li>• Systemic Association – Carney</li> </ul>	<h4>Stromal Tumor</h4> <ul style="list-style-type: none"> <li>• CD34 (+)</li> <li>• S100 (-)</li> <li>• Smooth muscle (-)</li> <li>• Benign, no association</li> </ul>
--	--

bascompalmer.org

### Conjunctival stromal tumour (COST): anterior-segment OCT findings

Joyeeta Das,<sup>1</sup> Samar K Basak,<sup>2</sup> Nilbedita Das<sup>2</sup>





Figure 1 Slit lamp examination of the right eye showing a well-demarcated, pink, fleshy and semi-translucent mass on the temporal bulbar conjunctiva.

Figure 2 Anterior-segment optical coherence tomography of the mass revealed a dome-shaped hyperreflective lesion. The mass, bounded by the hyperreflective corneal layer, the maximum height of the mass was 2.88 mm with subepithelial mass shadowing.

bascompalmer.org

### Summary



- Conjunctival Stromal tumor
- Benign lesion
- No regrowth 3 months after resection
- Importance of examination, imaging and histopathologic evaluation

bascompalmer.org

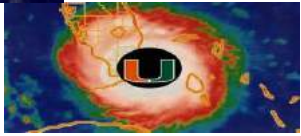
### Acknowledgement

- Carol Karp, MD
- Eric Hanson, MD
- Umangi Patel, MD

bascompalmer.org



Thank You !



# **Telesalud/ Oftalmología Global** **Telehealth/Global Ophthalmology**

**Innovaciones Tecnológicas en el  
Bascom Palmer Eye Institute**

Technological Innovations at  
Bascom Palmer Eye Institute



**Dr. Ranya G. Habash**



## Technology Innovation At Bascom Palmer Eye Institute

**Ranya Habash, MD**  
 Medical Director, Technology Innovation  
 Assistant Professor of Clinical Ophthalmology  
 Bascom Palmer Eye Institute  
 University of Miami




## A Renaissance Age in Medicine


With crisis comes opportunity...



## Brain-Machine Interface


*"Anything we can measure, we can control..."*

- Glaucoma
- Ocular Pain
- Alzheimer's Disease
- Parkinson's Disease
- Vascular Dementia
- Multiple Sclerosis
- HIV Encephalopathy



Healthy control  
 Early glaucoma  
 Advanced glaucoma


MNI z coordinate: -10 14



## Brain-Machine Interface

**Bascom Palmer + Kernel**

- Non-invasive helmet covered in sensors
- Flow: monitors blood flow
- Flux: measures electromagnetic activity
- Wearable, mobile, inexpensive fMRI
- Neuroscience-as-a-Service (Naas)





## Telemedicine at BPEI

- Virtual Urgent Care
- New, Follow-up, Post-Ops
- Virtual Counseling
- 2<sup>nd</sup> Opinion Consults
- Doctor-Doctor Consults
- Hybrid Tele-Visits & Video SLE
- Drive-Thru IOP Checks
- Resident/ER Tele-Staffing
- Remote Home Monitoring
- Online Communication




## Telemedicine at BPEI

- Doctor-Doctor Consults (international & domestic)
- 2<sup>nd</sup> Opinion Consults
- Virtual Counseling

### Telemedicine at BPEI

### Medical Innovation

- Ocular Surface Cancer Treatment
- ROP Treatment
- Photodynamic Therapy

57 yo Hispanic male  
OSSN s/p 4 cycles 5-FU

Actual patient treated with this system, successfully stopped pterygiums' induction. Fine vascular tissue not to perforation or permanent blindness

### Surgical Innovation

- Gene Therapy
- 3D Printed Eye
- 3D Surgery
- Bionic Eye –Argus
- Premium Cataract Surgery
- Laser Refractive Surgery

### Gene Therapy

- Step 1: Inject healthy copy of gene into retina
- Step 2: Healthy gene replaces defective gene
- Step 3: Cell makes normal proteins using healthy gene

"I can see a rainbow for the first time!"

Other conditions?  
Parkinson's Disease  
Cancer  
Aging  
COVID-19

### 3D Printed Eyes

- Cost: \$500 vs \$15,000
- Time: Hours vs Weeks
- Access: Digital file can be uploaded anywhere

Created digitally. Faster. Better. Cheaper.

### Software Technology

"Artificial intelligence represents one of technology's most important priorities, and healthcare is perhaps AI's most urgent application"

Satya Nadella  
CEO, Microsoft

## Artificial Intelligence

- Macular Degeneration
- Glaucoma
- Diabetic Retinopathy
- Ocular Melanoma
- Retinopathy of Prematurity
- Childhood Myopia
- Alzheimer's Disease

Bascom Palmer  
Collaborative Network  
for  
Data Sharing & AI

**Multi-Disease Retinal Imaging AI**  
Innovation by Bascom Palmer Eye Institute,  
Powered by Microsoft Cloud+AI Platform

Initial data set of 80,000 retinal images  
Deep convolutional neural network  
Macular Degeneration, Glaucoma, Melanoma, Diabetic Retinopathy, Myopia

Microsoft Bascom Palmer Eye Institute

## Artificial Intelligence

Bascom Palmer  
Collaborative Network  
for  
Data Sharing & AI

"With Bascom Palmer's physicians and scientists collaborating with others around the world, there is an even more robust set of geographic, ethnic, and socioeconomic data to power the algorithm. It is Bascom Palmer's commitment to unite the world and help patients through technology."  
— Dr. Arny Nathan



## Diagnostic + Therapeutic AI



Vision Obstacle  
Course



## Software Technology

	Normal Vision	Blurred Vision	Augmented Vision
Double Vision			
Macular Degeneration Distortion			
Macular Degeneration Central effects			

Vision Augmentation

## Research Innovations to Come...

- Biophysics Lab
- Orbital Vision Research Center
- Ocular Oncology Lab
- Retinal Neuroplasticity Lab
- Molecular Genetics Lab
- Stem Cells and Gene Therapy
- Pediatric Glaucoma Center
- Retinal Degenerations & Vascular Disorders Lab
- Center for Hereditary Retinal Disease
- Center for Molecular Ophthalmology & Neuroscience



Welcome to the Future  
at Bascom Palmer Eye Institute



# **Telesalud/ Oftalmología Global** **Telehealth/Global Ophthalmology**

**Modelos Emergentes y la Colaboración  
en la Oftalmología Global**

Emerging Models and Collaboration in  
Global Ophthalmology



**Dr. Zubair Ansari**

## Effective Models in Global Ophthalmology

Zubair Ansari, MD  
Assistant Professor

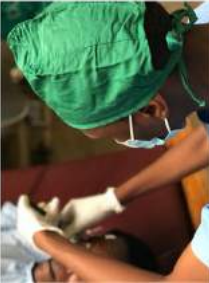Co-Director of International Physician Education  
Medical Director of Community Outreach  
Bascom Palmer Eye Institute, Miami FL



## Financial Disclosures

- None

## The Scope of the Problem

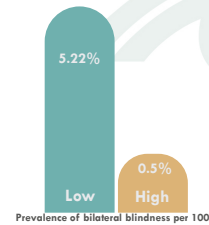


**2.2 Billion people suffer from visual impairment**

**Nearly 50% of visual impairment is considered "avoidable"**

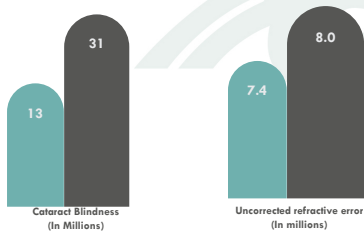
## Income Disparity and Bilateral Blindness

Low and low-middle income countries have higher prevalence of visual impairment per the World Health Organization (2020)



## What's to come...

The rate of blindness and visual impairment globally is only going to increase (projections 2030)



## How do we define "Global" Ophthalmology?

- Traditional models of global ophthalmology was often conflated with "global surgery" or **international** ophthalmology
- Newer models/thought leaders define global ophthalmology as the care and delivery of ophthalmological services in **under resourced** or **underserved** areas



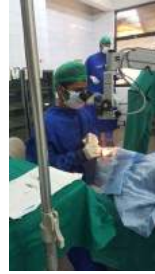Why is that distinction important? Because we don't need to travel far to practice global ophthalmology...

- Health disparities exist within our communities (particularly minorities or marginalized)
- Multiple studies have confirmed disparities in **access, quality, and outcomes of care** with regards to race and ethnicity in US



Clancy CM, Stryer DL. Racial and ethnic disparities and primary care experience. *Health Serv Res.* 2003;36(6 Pt 1):1779-98.  
Mortenson K, Chen J. The great recession and racial and ethnic disparities in health services use. *JAMA Intern Med.* 2013;173(4):315-17. doi:10.1001/jamaintern.2013.1414

## Cataract Camps

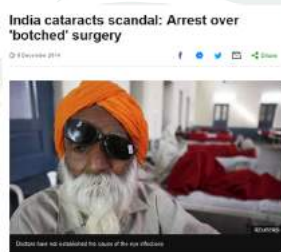

- Multiple published data on favorable short-term outcomes and complication rates
- With the advent of manual small incision cataract surgery, can now have little drain on resources

Kapoor R, Chatterjee A, David R, et al. Evaluation of visual outcome of cataract surgery in an Indian eye camp. *Bratisl J Ophthalmol.* 2009;53:452-456.

## Cataract Camp Pitfalls

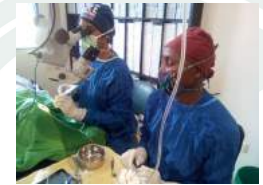- Can decimate local eye care providers
- May not have a "safety net" for patients who have adverse outcomes



<https://www.bbc.com/news/world-asia-india-30341213>

## Moving away from cataract camp models

- Collaboration with academic institutions and local eye care providers to provide a long-term **sustainable** solution
- Cross collaboration with resident exchange programs



## India – LV Prasad Eye Institute



LV Prasad Eye Institute, Hyderabad

### "Tiered" Payment System

- All patients receive the same care irrespective of payment status
  - But the hospital is supported by patients who pay for services
- Higher payers are offered more customizable treatment options (Premium IOLS/Multifocals/Femtosecond laser, etc)
- Robust training programs



## WHO Action Plan 2014 -2019 and Vision 20/20

- Set for an action plan for reduction of global blindness
  - Set forth 3 objectives
    1. Address the need for generating evidence on the magnitude and causes of visual impairment
    2. Encourages the development and implementation of integrated national eye health policies, plans and programs to enhance universal eye health
    3. Objective 3 addresses **multisectoral** engagement and effective **partnerships** to strengthen eye health
- The Global Initiative was set up to: "Intensify and accelerate prevention of blindness activities so as to achieve the goal of eliminating avoidable blindness by 2020."

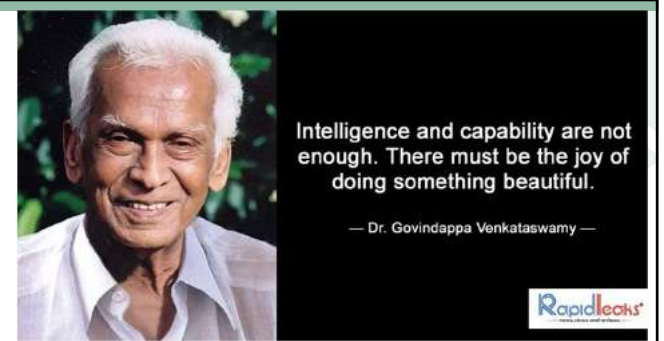


## What to do next...?



## Parting thoughts...

- 2.2 Billion people seems like an insurmountable number for one organization or one person
- Galvanize interest in global ophthalmology to create preferred practice patterns
- Standardization of highly effective models
- Continued checkpoints



## References

1. Robin AL, Ravilla T, Venkatesh R. Combating Cataract Blindness. *JAMA Ophthalmol* 2017;135(2):94-5.
2. Resnikoff S, Keys TU. Future trends in global blindness. *Indian J Ophthalmol* 2012;60(5):387-95.
3. Pascolini D, Mariotti SP. Global estimates of visual impairment: 2010. *Br J Ophthalmol* 2012;96(5):614-8.
4. Bourne RRA, Flaxman SR, Braithwaite T, et al. Magnitude, temporal trends, and projections of the global prevalence of blindness and distance and near vision impairment: a systematic review and meta-analysis. *Lancet Glob Health* 2017;5(9):e888-e97.
5. Dandona L, Dandona R. What is the global burden of visual impairment? *BMC Med* 2006;4:6.
6. Resnikoff S, Pascolini D, Mariotti SP, Pokharel GP. Global magnitude of visual impairment caused by uncorrected refractive errors in 2004. *Bull World Health Organ* 2008;86(1):63-70.
7. Babu BSG, Ravilla TD. Evidence-based management of eye care delivery. *Community Eye Health* 2018;31(102):S15-S6.
8. World Health Organization. *Global Action Plan 2014 – 2019*
9. Sommer A, Taylor HR, Ravilla TD, et al. Challenges of Ophthalmic Care in the Developing World. *JAMA Ophthalmol*. 2014;132(5):640-644. doi:10.1001/jamaophthalmol.2014.84
10. Ravilla T. Inequities in eye care in South Asia. *Community Eye Health* 2016;29(95):S01-S3. doi:10.1001/archophthalmol.2011.299
11. Sommer A. Ophthalmology Goes "Global". *Arch Ophthalmol*. 2011;129(10):1368-1369.
12. Clancy CM, Stryer DB. Racial and ethnic disparities and primary care experience. *Health Serv Res*. 2001;36(6 Pt 1):979-986.
13. Mortensen K, Chen J. The great recession and racial and ethnic disparities in health services use. *JAMA Intern Med*. 2013;173(4):315-317. doi:10.1001/jamainternmed.2013.1414

## Acknowledgements



- Dr. Eduardo Alfonso
- Dr. Carol Karp
- Dr. Steven Gedde
- All of our partners
- CURSO

# **Baja Vision Low Vision**

**Rehabilitación para los Pacientes de  
Visión Disminuida**

Vision Rehabilitation for Low Vision Patients



**Dr. Laura C. Sperazza**

# Vision Rehabilitation Options for Patients with Low Vision

Laura Sperazza, OD  
Director of Low Vision Services



"I'm sorry, nothing else can be done"  
Is NOT the answer



Copyright © 2018, Lighthouse Guild

What can you do to help your patients function *visually* when medical options have been exhausted?



Copyright © 2018, Lighthouse Guild

## Rehabilitation

.....a standard part of good medical care.



Copyright © 2018, Lighthouse Guild

## Rehabilitation

What is vision rehabilitation?

What can it do for my patients?

How can I access these services for my patients?



Copyright © 2018, Lighthouse Guild

## Vision Rehabilitation Options

None of these options restore sight to normal.

What they do is restore FUNCTION.



Copyright © 2018, Lighthouse Guild

## Four Major Causes of Vision Loss

Cataracts      Diabetic Retinopathy

Glaucoma      Macular Degeneration

Lighthouse Guild  
Copyright © 2018, Lighthouse Guild

## Cataracts

Clouding of the lens causes:

Normal      Normal      Normal

Overall blur      Loss of contrast      Increased glare

Lighthouse Guild  
Copyright © 2018, Lighthouse Guild

## Diabetic Retinopathy

Causes multiple visual impairments:

- Scotomas in vision
- Blurred vision
- Increased glare
- Loss of central and peripheral vision
- Decreased contrast sensitivity

Lighthouse Guild  
Copyright © 2018, Lighthouse Guild

## Glaucoma

- Loss of peripheral vision
- Increased glare sensitivity

Lighthouse Guild  
Copyright © 2018, Lighthouse Guild

## Macular Degeneration

Loss of central vision

**What It's Like**

This is how a street scene looks with normal vision.      Example of a Macular Degeneration.

The center of the macula is called the fovea and is responsible for fine detail vision - our central (or reading) vision, both for distance and close up. When the eye is directed at an object to be seen, whichever part is focused on the fovea will be the clearest, the most

Lighthouse Guild  
Copyright © 2018, Lighthouse Guild

## How does vision loss impact your patient's lives?

Most people have trouble with blurry images that are sometimes blurry only when they look at things that are far away. This is called blurry vision. Blurry vision is not a disease, but it can be a sign of a problem. Most people have trouble seeing things that are far away. This is called blurry vision. Blurry vision is not a disease, but it can be a sign of a problem.

Normal      Blurred (Cataract)

Most people have trouble with blurry images that are sometimes blurry only when they look at things that are far away. This is called blurry vision. Blurry vision is not a disease, but it can be a sign of a problem.

Normal      Blurred (Cataract)

Most people have trouble with blurry images that are sometimes blurry only when they look at things that are far away. This is called blurry vision. Blurry vision is not a disease, but it can be a sign of a problem.


Central Field Loss / Scotoma - (Macular Degeneration)      Overall Peripheral Field Loss (Glaucoma)

Lighthouse Guild  
Copyright © 2018, Lighthouse Guild

## The Impact of Vision Loss

Vision loss impacts a patient's:

- Independent living
- Travel and mobility
- Work and school
- Mental health

 Copyright © 2018, Lighthouse Guild


## The Impact of Vision Loss

Vision loss impacts a patient's:

- Independent living
- Travel and mobility
- Work and school
- Mental health

**Independent living**

- Read mail, medication, food labels and newsprint
- Write a check
- Dial a telephone
- Shop for groceries
- Prepare meals and cook
- Participate in hobbies / activities

 Copyright © 2018, Lighthouse Guild


## The Impact of Vision Loss

Vision loss impacts a patient's:

- Independent living
- Travel and mobility
- Work and school
- Mental health

**Travel and mobility**

- Cross streets
- Read street and bus signs
- Drive a car
- Recognize faces
- Socialize

 Copyright © 2018, Lighthouse Guild


## The Impact of Vision Loss

Vision loss impacts a patient's:

- Independent living
- Travel and mobility
- Work and school
- Mental health

**Work and school**

- Use a computer
- Use a tablet and/or phone
- Read and write
- Travel to and from work/school
- Lost job, income, dignity
- Dependent on strangers

 Copyright © 2018, Lighthouse Guild

## The Impact of Vision Loss


Vision loss impacts a patient's:

- Independent living
- Travel and mobility
- Work and school
- Mental health

**Patients may feel:**

- Depressed
- Isolated
- Embarrassed
- Anxious
- Abandoned

*Rehabilitation should be a part of good care.*

 Copyright © 2018, Lighthouse Guild

## Vision Rehabilitation Options

- 1 Low vision examination and devices
- 2 Activities of daily living
- 3 Orientation and mobility instruction
- 4 Adaptive technology training
- 5 Behavioral health services



 Copyright © 2018, Lighthouse Guild

## Vision Rehabilitation Options

### Low vision examination and devices

- History
- Distance and near acuity
- Refraction
- Visual field
- Contrast and glare sensitivity
- Visual skills and binocularity
- Color vision

Gears rehabilitation



Copyright © 2018, Lighthouse Guild

## Low Vision Evaluation

The goal is to determine:

- 1 Where is the patient now?
- 2 Where do they want to be?
- 3 What interventions can get them there?



Copyright © 2018, Lighthouse Guild

## Low Vision Devices

- One device rarely meets all needs
- Consider the patient's vision, goals, and abilities
- Devices are task specific!



Copyright © 2018, Lighthouse Guild

## Spectacles

### Advantages

- Widest field of view
- Monocular or binocular
- Hands-free

### Disadvantages

- Close working distance
- Field reduces as power increases
- No illumination



Copyright © 2018, Lighthouse Guild

## Hand-Held Magnifiers

- More complicated to use than spectacles
- Reading material must be held while focusing the magnifier at or near the focal point, so both hands are occupied
- More useful for short term tasks



Copyright © 2018, Lighthouse Guild

## Stand Magnifiers

Helpful for continuous reading

Best for children and patients who:


- Have difficulty maintaining lens focus
- Cannot hold a hand-held device (e.g. hand tremors or arthritis)



Copyright © 2018, Lighthouse Guild

## Telescopes

- The only optical aid for distance viewing
- Come in a variety of types
- Used for scanning and identifying objects




**Lighthouse Guild**  
Copyright © 2018, Lighthouse Guild

## Telescopes


**Binocular and hand-held**

- Best for mobility
- Provide a larger field of view
- Convenient for spotting objects



**Spectacle mounted**


- For tasks where higher magnification is not needed
- Can be used for driving in some states



**Lighthouse Guild**  
Copyright © 2018, Lighthouse Guild

## Electronic Video Magnifiers


- Used for reading, writing and identifying small objects
- Desktop, hand-held and portable versions
- Desktop video magnification systems
- Enlarges reading material up to 60 times
- Enhance and reverse contrast (e.g white text on dark background)



**Lighthouse Guild**  
Copyright © 2018, Lighthouse Guild

## Electronic Video Magnifiers

- Hand-held and portable versions
- Good for reading food labels, price tags, medicine bottles, etc.
- Can have rollers for flat surfaces
- Some have auto-focusing, color options and image capturing



**Lighthouse Guild**  
Copyright © 2018, Lighthouse Guild


## Electronic Video Magnifiers

**Advantage**

- Can sit at normal viewing distance

**Disadvantage**

- Not portable
- Relatively expensive




**Lighthouse Guild**  
Copyright © 2018, Lighthouse Guild

## Vision Loss Impacts Performance

Patients with vision loss have poorer performance in ADLs and IADLs.

**Safety may also be impacted:**

- Medication errors
- Product misuse
- Injuries and falls
- Errors in financial management



**Lighthouse Guild**  
Copyright © 2018, Lighthouse Guild

## Vision Rehabilitation Options

Rehabilitation for activities of daily living (ADL) and instrumental activities of daily living (IADL)

**Lighthouse Guild**  
Copyright © 2018, Lighthouse Guild

## Vision Rehabilitation Addresses Specific Tasks

Areas often addressed include:

- Reading and writing
- Meal preparation
- Health and wellness
- Environmental modifications
- Indoor and outdoor mobility
- Adaptive technology

**Lighthouse Guild**  
Copyright © 2018, Lighthouse Guild

## Meal Preparation

Basic adaptations for meal preparation:

- Tactile markings ("hi-marks")
- Increased contrast
- Organization techniques
- Techniques for using sharps
- Liquid level indicator ("say-when")

**Lighthouse Guild**  
Copyright © 2018, Lighthouse Guild

## Health and Wellness

Simple approaches for health-related activities include:

- Large print and tactile pill organizers
- Autodrop eyedrop guide
- Talking glucometer for diabetic management
- Hand-held magnifier for diabetic foot checks

**Lighthouse Guild**  
Copyright © 2018, Lighthouse Guild

## Environmental Modifications

Approaches to improve performance and safety include:

- Create contrast between door and walls
- Contrasting handrails and markings on stairs
- Adequate and consistent lighting
- Window blinds to control glare

**Lighthouse Guild**  
Copyright © 2018, Lighthouse Guild

## Orientation and Mobility

Approaches for improving mobility include:

- Guide canes, dogs and electronic devices
- Orienting to a space and establishing travel routes
- Trailing for indoor travel
- The guide technique

Teaches skills to help the visually impaired travel safely and independently

**Lighthouse Guild**  
Copyright © 2018, Lighthouse Guild

## Adaptive Technology Training

### Technology increases access and solutions:

Adaptive computer equipment and software


Video magnification systems

Tablets and smartphones with accessibility feature

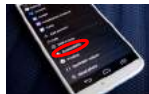
Apps designed for people with vision loss



High contrast keyboard



Magnification and voice output software



Accessibility features



Apps for tablet or smartphone



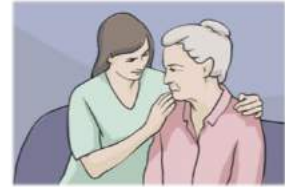Copyright © 2018, Lighthouse Guild

## The Impact of Vision Loss

Dramatically changes a patient's life

Often occurs at a time of other life losses

Many experience a grieving period



Copyright © 2018, Lighthouse Guild

## Psychosocial Well-Being

All patients may benefit from support services such as low vision support groups.

Helps deal with the fear, anxiety and anger

Learn problem solving and self management skills

Present the referral as guidance and support that will help improve independence.



Copyright © 2018, Lighthouse Guild

## Sharing the Diagnosis

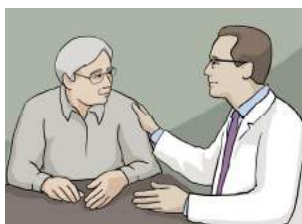The conversation is often difficult for both physicians and patients.

Reluctance to present the diagnosis should **NOT** interfere with patients' understanding their condition and receiving needed vision rehabilitation.



Copyright © 2018, Lighthouse Guild

## Sharing the Diagnosis



Discuss vision rehabilitation as a part of good care rather than something necessitated by a failure of care.

"Nothing else can be done" should never be an option.

A positive and empathetic attitude is key.



Copyright © 2018, Lighthouse Guild

## In Conclusion...

### Vision Rehabilitation must be presented:

In conjunction with medical, surgical and refractive care

At the inception of care



Copyright © 2018, Lighthouse Guild

**Thank you.**



250 West 64th Street  
New York, NY 10023  
[lighthouseguild.org](http://lighthouseguild.org)